



**PATIENT**

Tyson Luciani

**PRESENTING CLINICAL SIGNS**

Progressive lameness left front leg past 2 months

**SPECIES**

K9

**RADIOGRAPHIC STUDY OF THE ELBOWS & CARPI**

Mediolateral neutral and flexed and craniocaudal views of the elbows and mediolateral and dorsopalmar views of the carpi totaling 10 images available for review.

**BREED**

Mixed

**RADIOGRAPHIC FINDINGS**

Significant cranial contour blurring and decreased opacity are seen in the proximal aspect of the left medial coronoid process. There is a radioulnar step formation with a longer ulnar. Deformity of the cranial radial metaphysis is seen as well as subtrochlear notch sclerosis of the ulnar.

**SEX**

MN

The medial coronoid process of the right elbow is only minimally blurred. There is a minimal radioulnar step and minimal deformity of the cranial contour of the proximal radial metaphysis.

**AGE**

7 Months

No evidence of subchondral bone defects is noted in either of the elbows.

The carpal joints present within normal limits.

The distal radial and ulnar growth plates present within age related normal limits as well.

**INTERPRETED BY**

Nele Eley, DVM  
Dr. med. Vet. DipECVDI

**RADIOGRAPHIC DIAGNOSIS**

- Medial coronoid pathology of the left elbow.
- Minimal radiographic abnormality of the medial coronoid process in the right elbow.
- Normal radiographic presentation of the carpi.

**HOSPITAL NAME**

Blairstown Animal  
Hospital

**INTERPRETATION OF THE FINDINGS & FURTHER RECOMMENDATIONS**

The radiographic findings are compatible with medial coronoid pathology in the left elbow. The findings in the right elbow are equivocal for anatomic variant versus medial coronoid pathology. Arthroscopic revision of the left elbow should be considered and may be preceded by CT study of both elbows for further verification, especially for the right elbow.

**REFERRING VET**

Dr. Summers

**INVOICE**

55792

**DATE**

12-22-22



**PATIENT**

Tyson Luciani

**SPECIES**

K9

**BREED**

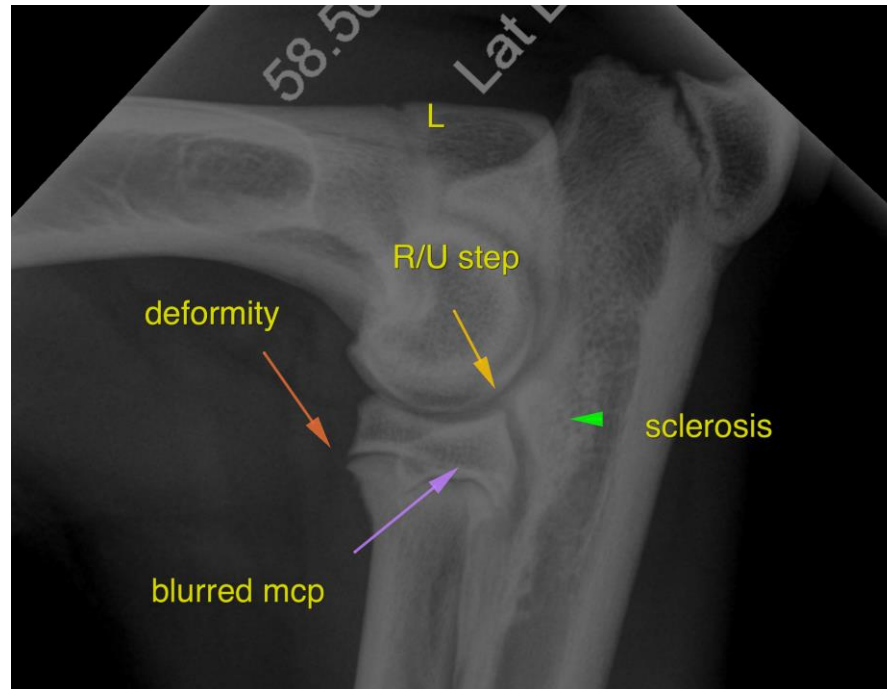
Mixed

**SEX**

MN

**AGE**

7 Months



**INTERPRETED BY**

Nele Eley, DVM  
Dr. med. Vet. DipECVDI

The information and recommendations provided are based on the images presented by the referring veterinarian/sonographer. No evaluation can be communicated regarding pathology that was not visible in the image/video clips provided.

Thank you for this referral. If the clinical or image interpretation does not parallel your findings or if I can be of any further assistance please contact me.

**HOSPITAL NAME**

Blairstown Animal  
Hospital

**Nele Eley**, DVM, Dr. med. vet., DipECVDI  
European Specialist in Veterinary Diagnostic Imaging, Cert. Radiology,  
Senior lecturer University of Giessen, Germany, Veterinary Faculty, Department of Radiology  
Nele.Eley@sonopath.com

**REFERRING VET**

Dr. Summers

**INVOICE**

55792

**DATE**

12-22-22