



PATIENT

River Jelks

PRESENTING CLINICAL SIGNS

Shoulder US - R/O concurrent tendinitis Painful with stretch and palpation SUP, BB and teres, triceps Suspect secondary to elbow OA and cervical IVDD - seen on rads
Abnormal PE/Chem/CBC/UA Results: Elbow OA - bilateral moderate IVDD significant C 5-6-7

SPECIES

Canine

ULTRASONOGRAPHIC FINDINGS

Left Shoulder

BREED

Pug

The supraspinatus, deltoideus and infraspinatus muscles present within normal limits for shape, volume, echoarchitecture and echogenicity. The transition to the supraspinatus tendon is even and thin. The broad part of the supraspinatus tendon presents within normal limits for its shape and volume. Minimal internal echoarchitectural remodeling of the supraspinatus tendon with no evidence of biceps impingement is seen. The supraspinatus tendon measures 4mm in average maximum thickness. The attachment to the bone surface of the greater humeral tubercle is even and smooth. The infraspinatus muscle condenses and narrows down to a long tendon of even width, smooth outline and regular echogenic fibular echoarchitecture and up to the attachment to the bone surface of the humerus. There is no evidence of enlargement of the infraspinatus bursa.

SEX

FS

AGE

8

The biceps tendon can be seen from its origin through the bicipital groove, up to the musculotendinous transition and is within normal limits for shape, echogenicity and echoarchitecture. There is no evidence of synovial thickening and no evidence of abnormal effusion. The bone surface of the bicipital groove is even and smooth.

INTERPRETED BY

Nele Eley, DVM
Dr. med. Vet. DipECVDI

The visible margins of the shoulder joint are within normal limits.

Right Shoulder

HOSPITAL NAME

Animal Care Center of
Castle Pines

The supraspinatus, deltoideus and infraspinatus muscles present within normal limits for shape, volume, echoarchitecture and echogenicity. The transition to the supraspinatus tendon is even and thin. The broad part of the supraspinatus tendon presents within normal limits for its shape and volume. Minimal internal echoarchitectural remodeling of the supraspinatus tendon with no evidence of biceps impingement is seen. The supraspinatus tendon measures 4mm in average maximum thickness. The attachment to the bone surface of the greater humeral tubercle is even and smooth. The infraspinatus muscle condenses and narrows down to a long tendon of even width, smooth outline and regular echogenic fibular echoarchitecture and up to the attachment to the bone surface of the humerus. There is no evidence of enlargement of the infraspinatus bursa.

REFERRING VET

Bartling

The biceps tendon can be seen from its origin through the bicipital groove, up to the musculotendinous transition and is within normal limits for shape, echogenicity and echoarchitecture. There is no evidence of synovial thickening and no evidence of abnormal effusion. The bone surface of the bicipital groove is even and smooth.

INVOICE

55801

The visible margins of the shoulder joint are within normal limits.

DATE

12-22-22



PATIENT

River Jelks

ULTRASONOGRAPHIC DIAGNOSIS

- Normal age related findings of the rotator cuff and biceps tendons in both shoulders.

SPECIES

Canine

INTERPRETATION OF THE FINDINGS & FURTHER RECOMMENDATIONS

The ultrasonographic study reveals normal anatomic relationships considering age and size of the patient in both shoulders with no evidence of rotator cuff injury or biceps tenosynovitis. It appears that no concurrent shoulder pathology contributes to the clinical signs of the patient based on the negative ultrasonographic findings.

BREED

Pug

SEX

FS

AGE

8

INTERPRETED BY

Nele Eley, DVM
Dr. med. Vet. DipECVDI

HOSPITAL NAME

Animal Care Center of
Castle Pines

REFERRING VET

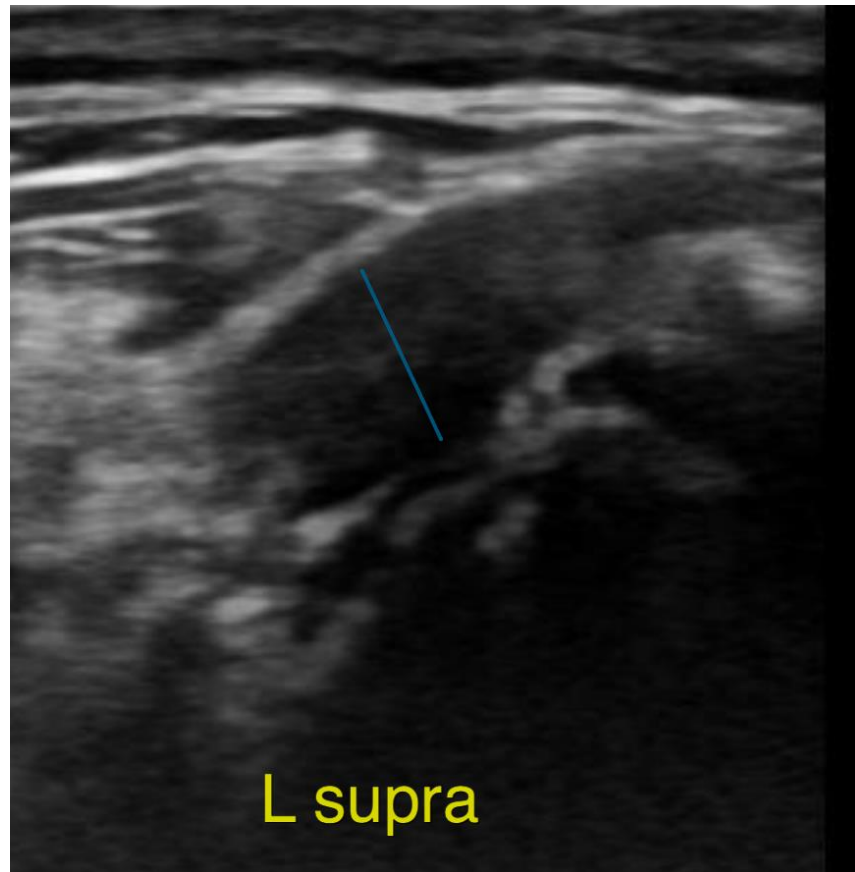
Bartling

INVOICE

55801

DATE

12-22-22





PATIENT

River Jelks

SPECIES

Canine

BREED

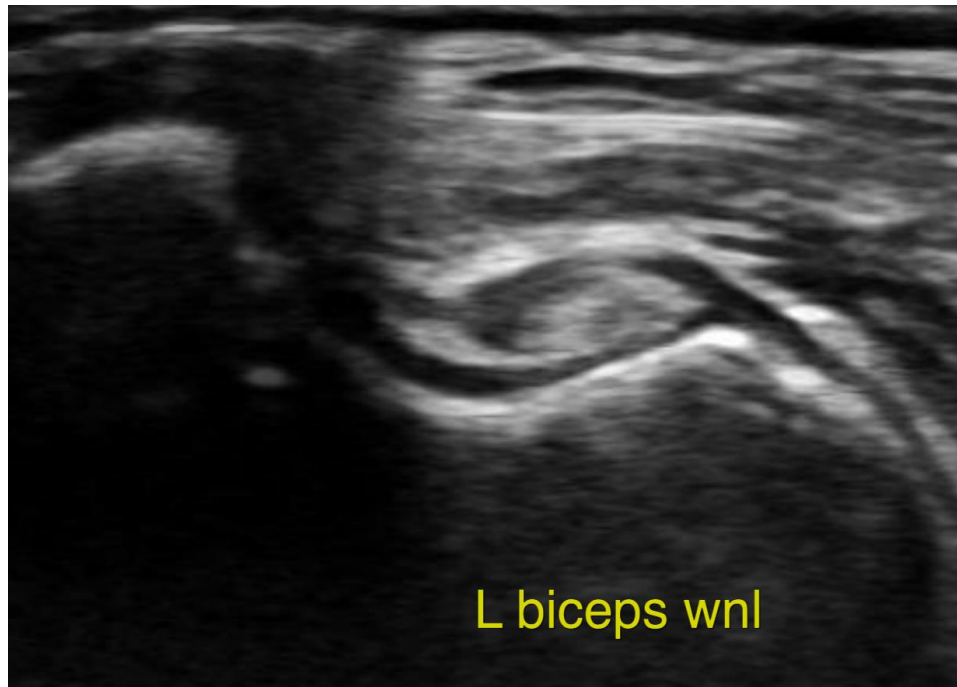Pug

SEX

FS

AGE

8



INTERPRETED BY

Nele Eley, DVM
Dr. med. Vet. DipECVDI

The information and recommendations provided are based on the images presented by the referring veterinarian/sonographer. No evaluation can be communicated regarding pathology that was not visible in the image/video clips provided.

Thank you for this referral. If the clinical or image interpretation does not parallel your findings or if I can be of any further assistance please contact me.

HOSPITAL NAME

Animal Care Center of
Castle Pines

Nele Eley, DVM, Dr. med. vet., DipECVDI
European Specialist in Veterinary Diagnostic Imaging, Cert. Radiology,
Senior lecturer University of Giessen, Germany, Veterinary Faculty, Department of Radiology
Nele.Eley@sonopath.com

REFERRING VET

Bartling

INVOICE

55801

DATE

12-22-22