



**PATIENT**

Clyde Joanis

**PRESENTING CLINICAL SIGNS**

urinating less than usual, has a hx of crystalluria  
Abnormal PE/Chem/CBC/UA Results: BW- WNL

**SPECIES**

Feline

**RADIOGRAPHIC STUDY OF THE ABDOMEN**

Right/left lateral and ventrodorsal whole body views totaling 3 images available for review.

Abdominal read requested.

**BREED**

Domestic Shorthair

**RADIOGRAPHIC FINDINGS**

The surrounding bony structures are within normal limits.

**SEX**

Male

No abnormalities of the extraabdominal soft tissues are noted. The abdominal wall is smooth and thin.

**AGE**

2 Years

The serosal detail is maintained throughout the peritoneal and retroperitoneal space.

The liver is appropriate in position, size and presents uniform opacity.

The splenic head is in the anticipated position and within normal limits for size and opacity. The splenic tail is not seen.

**INTERPRETED BY**

Nele Eley, DVM  
Dr. med. Vet. DipECVDI

Both kidneys are seen and present with normal size, shape, delineation and opacity.

The urinary bladder is moderately distended. No evidence of radiopaque calculi is seen.

The stomach is in its anticipated position and presents normal content.

**HOSPITAL NAME**

St. Catherine's Animal  
Hospital

The small intestinal loops are of even diameter and non-dilated, a small amount of gas is seen within the small intestinal loops and considered within normal limits.

The colon is seen in the expected position and presents with appropriate content.

**REFERRING VET**

Dr. Jui Gokhale

**RADIOGRAPHIC DIAGNOSIS**

- Normal radiographic presentation of the urinary bladder.

**INTERPRETATION OF THE FINDINGS & FURTHER RECOMMENDATIONS**

**INVOICE**

55799

The urinary bladder presents within normal limits. No radiopaque calculi are seen. The urinary bladder is moderately distended which does not rule out but also does not really suggest presence of decrease in urine production. Further definition by means of abdominal ultrasound and full urinalysis as well as bloodwork could be considered if not performed already.

**DATE**

12-22-22



**PATIENT**

Clyde Joanis

**SPECIES**

Feline

**BREED**

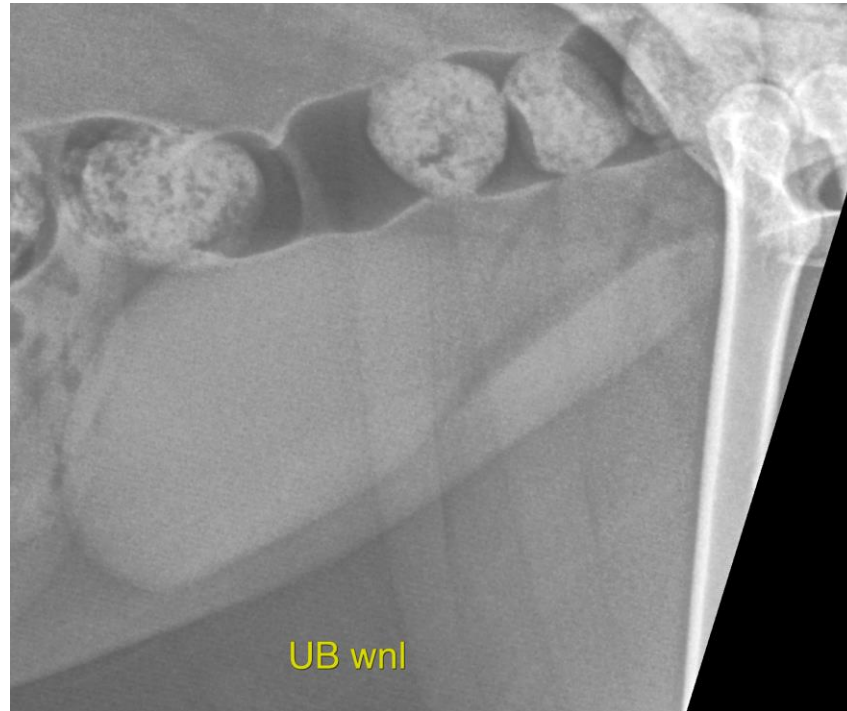
Domestic Shorthair

**SEX**

Male

**AGE**

2 Years



**INTERPRETED BY**

Nele Eley, DVM  
Dr. med. Vet. DipECVDI

The information and recommendations provided are based on the images presented by the referring veterinarian/sonographer. No evaluation can be communicated regarding pathology that was not visible in the image/video clips provided.

**HOSPITAL NAME**

St. Catherine's Animal  
Hospital

Thank you for this referral. If the clinical or image interpretation does not parallel your findings or if I can be of any further assistance please contact me.

**Nele Eley**, DVM, Dr. med. vet., DipECVDI  
European Specialist in Veterinary Diagnostic Imaging, Cert. Radiology,  
Senior lecturer University of Giessen, Germany, Veterinary Faculty, Department of Radiology  
Nele.Eley@sonopath.com

**REFERRING VET**

Dr. Jui Gokhale

**INVOICE**

55799

**DATE**

12-22-22