



PATIENT

Boo Kaplan

PRESENTING CLINICAL SIGNS

MET CHECK

SPECIES

Feline

RADIOGRAPHIC STUDY OF THE THORAX

Right/left lateral and dorsoventral views of the thorax totaling 3 images available for review.

RADIOGRAPHIC FINDINGS

BREED

DSH

The surrounding bony structures are within normal limits.

SEX

NM

The extrathoracic soft tissues present homogeneous without abnormalities.

The heart is of normal size and shape and there is no evidence of cardiac chamber or vascular enlargement. The pulmonary vasculature is within normal limits. The vertebral heart score is 7.5.

The cranial mediastinum presents the expected soft tissue opacity. The mediastinal width is less than twice the width of the vertebral column at the same level.

AGE

5 Years, 8 Months

The trachea is normal in diameter and presents the anticipated course. The luminal outline of the trachea is smooth.

Mild esophageal as well as mild gastric aerophagia are noted.

INTERPRETED BY

Nele Eley, DVM
Dr. med. Vet. DipECVDI

The bronchial tree presents with thin walls and tapers uniformly towards the periphery as expected.

The lung parenchyma presents the expected architecture and opacity. The intrapulmonary vascular branching is seen up to the third order lung vessels.

HOSPITAL NAME

DPC Veterinary
Hospital

The diaphragm is well delineated with even surface and the expected mild cranial bulging of the diaphragmatic cupola.

RADIOGRAPHIC DIAGNOSIS

- Normal age related thorax with no evidence of pulmonary metastases.

REFERRING VET

Dr. Rivera

INTERPRETATION OF THE FINDINGS & FURTHER RECOMMENDATIONS

The radiographic study reveals no evidence of interstitial pulmonary nodules or mediastinal lymphadenomegaly. The radiographic presentation of the thorax is within age related normal limits.

INVOICE

55790

DATE

12-22-22



PATIENT

Boo Kaplan

SPECIES

Feline

BREED

DSH

SEX

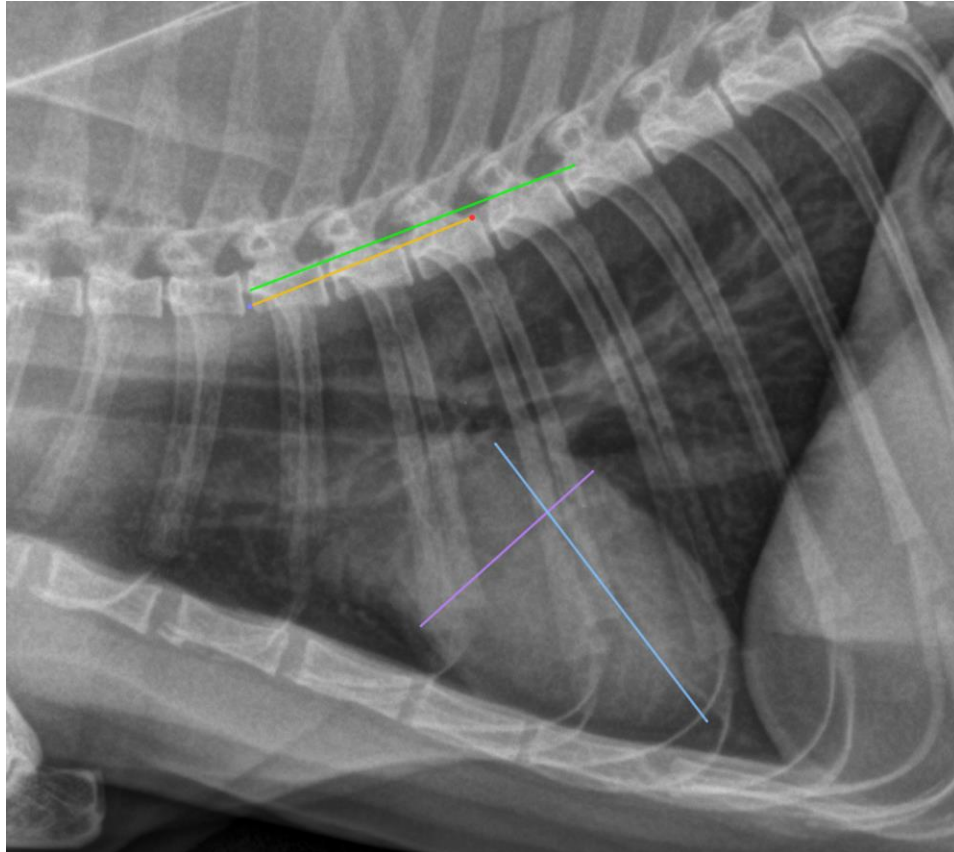
NM

AGE

5 Years, 8 Months

INTERPRETED BY

Nele Eley, DVM
Dr. med. Vet. DipECVDI



HOSPITAL NAME

DPC Veterinary
Hospital

REFERRING VET

Dr. Rivera

INVOICE

55790

DATE

12-22-22

The information and recommendations provided are based on the images presented by the referring veterinarian/sonographer. No evaluation can be communicated regarding pathology that was not visible in the image/video clips provided.

Thank you for this referral. If the clinical or image interpretation does not parallel your findings or if I can be of any further assistance please contact me.

Nele Eley, DVM, Dr. med. vet., DipECVDI
European Specialist in Veterinary Diagnostic Imaging, Cert. Radiology,
Senior lecturer University of Giessen, Germany, Veterinary Faculty, Department of Radiology
Nele.Eley@sonopath.com