

**PATIENT**

Renny Sirstins

PRESENTING CLINICAL SIGNS

long history of coughing, worse recently
Abnormal PE/Chem/CBC/UA Results: none taken, is otherwise healthy and owner declined additional testing

SPECIES

Canine

RADIOGRAPHIC STUDY OF THE THORAX

Right/left lateral and ventrodorsal views totaling 3 images available for review.

BREED

Pomeranian

RADIOGRAPHIC FINDINGS

Multiple spondyloses are present throughout the cervical and thoracic spine.

The extrathoracic soft tissues present homogeneous without abnormalities.

SEX

Neutered

The vertebral heart score is 11. However, shortening of the mid thoracic vertebrae is present and the vertebral heart score measurements may be inaccurate. No specific chamber enlargement is seen.

AGE

12 Years

The cranial mediastinum presents the expected soft tissue opacity. The mediastinal width is less than twice the width of the vertebral column at the same level.

Varying degrees of tracheal and bronchial collapse are seen on the right and left lateral images.

INTERPRETED BY

Nele Eley, DVM
Dr. med. Vet. DipECVDI

The degree of pulmonary inflation is fair. A mild generalized bronchointerstitial lung pattern is seen and considered within age related normal limits.

The diaphragm is well delineated with even surface and the expected mild cranial bulging of the diaphragmatic cupola.

HOSPITAL NAME

Q Street Animal
Hospital

RADIOGRAPHIC DIAGNOSIS

- Tracheal and bronchial collapse.
- Cervicothoracic spondyloses with short vertebrae in the mid thoracic spine.

REFERRING VET

Bretschneider

INTERPRETATION OF THE FINDINGS & FURTHER RECOMMENDATIONS

The main finding appears to be the presence of dynamic tracheal and bronchial disease which typically is secondary to degenerative bronchomalacia.

The mild bronchointerstitial lung pattern is thought to be within the age related normal limits and may be slightly enhanced by the fair inflation of the lung.

INVOICE

49202

DATE

12-22-21



PATIENT

Renny Sirstins

SPECIES

Canine

BREED

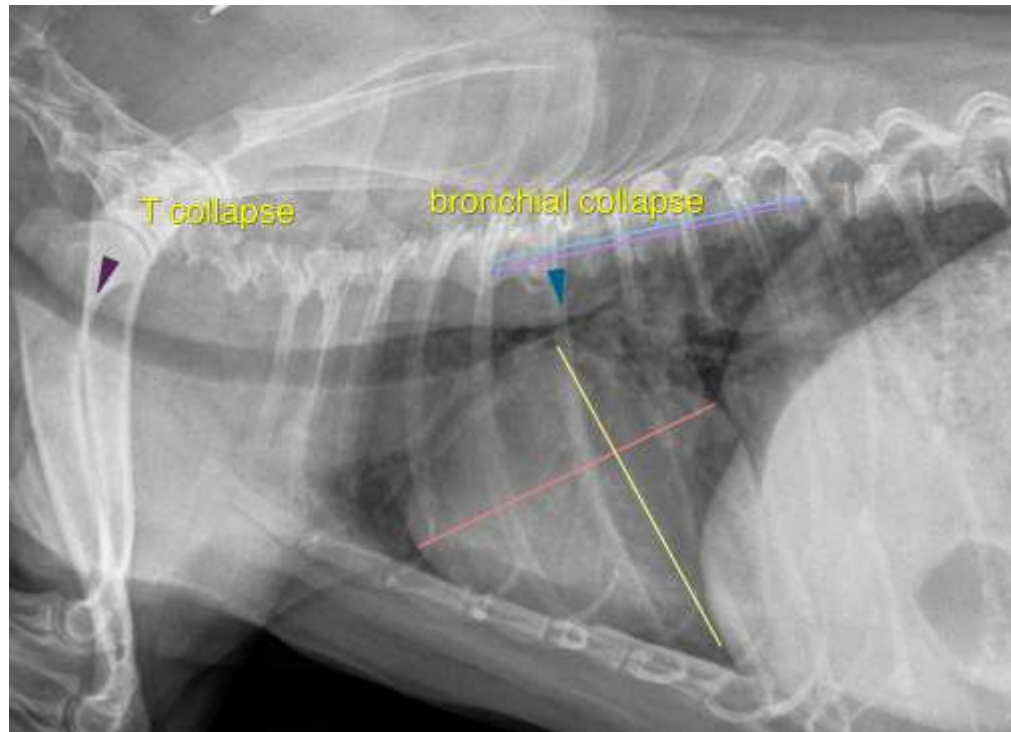
Pomeranian

SEX

Neutered

AGE

12 Years



INTERPRETED BY

Nele Eley, DVM
Dr. med. Vet. DipECVDI

The information and recommendations provided are based on the images presented by the referring veterinarian. No evaluation can be communicated regarding pathology that was not visible in the image/video clips provided.

HOSPITAL NAME

Q Street Animal
Hospital

Thank you for this referral. If the clinical or image interpretation does not parallel your findings or if I can be of any further assistance please contact me.

Nele Eley, DVM, Dr. med. vet., DipECVDI
European Specialist in Veterinary Diagnostic Imaging, Cert. Radiology,
Senior lecturer University of Giessen, Germany, Veterinary Faculty, Department of Radiology
Nele.Eley@sonopath.com

REFERRING VET

Bretschneider

INVOICE

49202

DATE

12-22-21