



PATIENT

Fozzie Woods

PRESENTING CLINICAL SIGNS

Otitis externa AD Pseudomonas aeruginosa for 2 months. Presenting with nystagmus and right sided head tilt after last dose of gento/keto/triamcinolone on 12/5 see attached records for detailed history

SPECIES

Canine

COMPUTED TOMOGRAPHIC STUDY OF THE HEAD

Plain and post contrast studies available for review.

BREED

Cocker Spaniel Mix

COMPUTED TOMOGRAPHIC FINDINGS

The brain presents no deviation from normal anatomy and symmetry. The grey and white matter distinction and the neuroparenchymal attenuation are as expected. The distribution of contrast enhancement is within normal limits throughout the parenchyma and meninges. The ventricular system is non-dilated and within the limits of the expected volume and symmetry.

SEX

MN

Thin and smoothly folded conchae and turbinates with even smooth mucosal lining.

AGE

6 Years

Both temporomandibular joints present congruent joint spaces with even subchondral bone surfaces and are considered within normal limits.

Moderate thickening of the epithelial lining of the right external auditory meatus is seen with increased contrast enhancement. There is a mild amount of hypoattenuating material within the medial aspect of the horizontal part of the right external auditory meatus. Both tympanic bullae are aerated, the mucosal lining is not seen, the bony wall is smooth and thin.

INTERPRETED BY

Nele Eley, DVM
Dr. med. Vet. DipECVDI

The right medial retropharyngeal lymph node presents mild symmetric enlargement with maintained short to long axis ratio and contrast enhancement.

HOSPITAL NAME

Stone Cottage
Veterinary Hospital

The salivary glands present within normal limits.

The visible dentition is within normal limits.

COMPUTED TOMOGRAPHIC DIAGNOSIS

- Moderate chronic right sided otitis externa.
- Right sided medial retropharyngeal lymphadenomegaly.

REFERRING VET

Spaccarelli

INTERPRETATION OF THE FINDINGS & FURTHER RECOMMENDATIONS

The CT study reveals no evidence of otitis media or interna. No intracranial pathology is seen. There are signs of moderate right sided chronic otitis externa with mild chronic inflammatory stenosis of the auditory meatus.

INVOICE

49198

The right medial retropharyngeal lymphadenomegaly is compatible with reactive hyperplasia.

DATE

12-22-21



PATIENT

Fozzie Woods

SPECIES

Canine

BREED

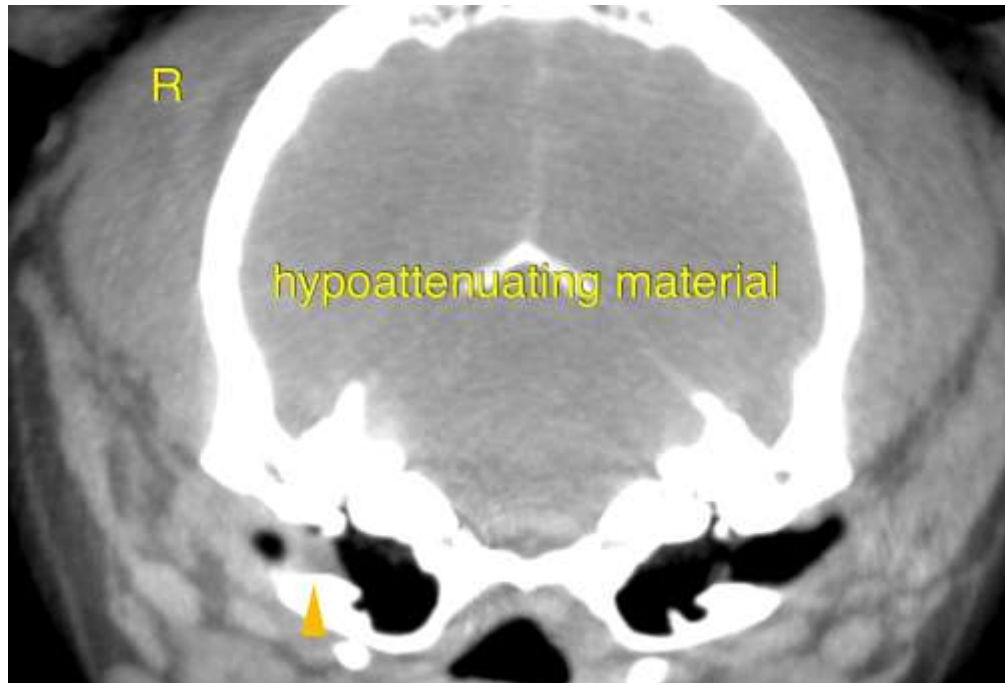
Cocker Spaniel Mix

SEX

MN

AGE

6 Years



INTERPRETED BY

Nele Eley, DVM
Dr. med. Vet. DipECVDI

The information and recommendations provided are based on the images presented by the referring veterinarian. No evaluation can be communicated regarding pathology that was not visible in the image/video clips provided.

Thank you for this referral. If the clinical or image interpretation does not parallel your findings or if I can be of any further assistance please contact me.

HOSPITAL NAME

Stone Cottage
Veterinary Hospital

Nele Eley, DVM, Dr. med. vet., DipECVDI
European Specialist in Veterinary Diagnostic Imaging, Cert. Radiology,
Senior lecturer University of Giessen, Germany, Veterinary Faculty, Department of Radiology
Nele.Eley@sonopath.com

REFERRING VET

Spaccarelli

INVOICE

49198

DATE

12-22-21