

**PATIENT**

Chloe Tufford

PRESENTING CLINICAL SIGNS

came for not eating and not pooping, x-ray was performed a week ago and diagnosed with Ileus today came for follow up because she is not eating much and not pooping still, heart looked enlarged, so 3 views was obtained for evaluation of the heart size and shape.

SPECIES

Canine

RADIOGRAPHIC STUDY OF THE THORAX

Right/left lateral and ventrodorsal whole body views totaling 3 images available for review.

BREED

Shih Tzu

Thoracic read requested.

RADIOGRAPHIC FINDINGS

The surrounding bony structures are within normal limits.

SEX

Female Spayed

The extrathoracic soft tissues present homogeneous without abnormalities.

The heart is of normal size and shape and there is no evidence of cardiac chamber or vascular enlargement. The pulmonary vasculature is within normal limits. The vertebral heart score is 8.5.

AGE

14 Years

The cranial mediastinum presents the expected soft tissue opacity. The mediastinal width is less than twice the width of the vertebral column at the same level.

INTERPRETED BY

Nele Eley, DVM
Dr. med. Vet. DipECVDI

The trachea is normal in diameter and presents the anticipated course. The luminal outline of the trachea is smooth.

The bronchial tree presents with thin walls and tapers uniformly towards the periphery as expected.

HOSPITAL NAME

St. Catherine's Animal
Hospital

The lung parenchyma presents the expected architecture and opacity. The intrapulmonary vascular branching is seen up to the third order lung vessels.

The diaphragm is well delineated with even surface and the expected mild cranial bulging of the diaphragmatic cupola.

REFERRING VET

Dr. Masoud

RADIOGRAPHIC DIAGNOSIS

- Normal age related thorax.

INTERPRETATION OF THE FINDINGS & FURTHER RECOMMENDATIONS**INVOICE**

49197

The radiographic presentation of the cardiac silhouette is within normal limits. The bronchopulmonary structures reveal no significant abnormality. All findings are considered within age related normal limits.

DATE

12-22-21



PATIENT

Chloe Tufford

SPECIES

Canine

BREED

Shih Tzu

SEX

Female Spayed

AGE

14 Years

INTERPRETED BY

Nele Eley, DVM
Dr. med. Vet. DipECVDI

HOSPITAL NAME

St. Catherine's Animal
Hospital

REFERRING VET

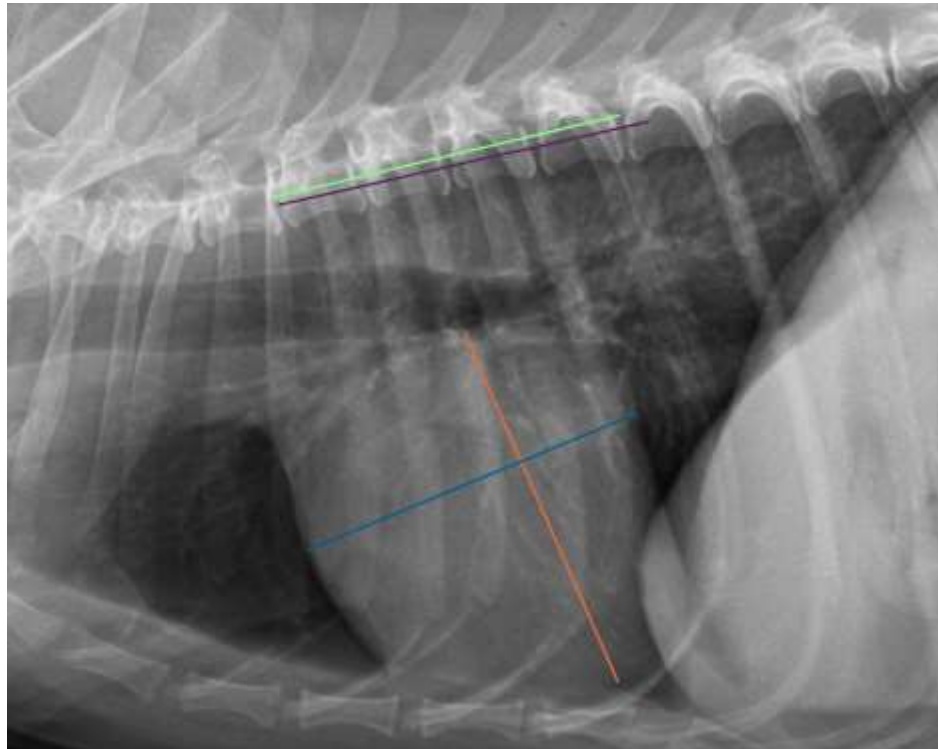
Dr. Masoud

INVOICE

49197

DATE

12-22-21



The information and recommendations provided are based on the images presented by the referring veterinarian. No evaluation can be communicated regarding pathology that was not visible in the image/video clips provided.

Thank you for this referral. If the clinical or image interpretation does not parallel your findings or if I can be of any further assistance please contact me.

Nele Eley, DVM, Dr. med. vet., DipECVDI
European Specialist in Veterinary Diagnostic Imaging, Cert. Radiology,
Senior lecturer University of Giessen, Germany, Veterinary Faculty, Department of Radiology
Nele.Eley@sonopath.com