



PATIENT PRESENTING CLINICAL SIGNS

Shadow Taylor
 Decreased energy per O, exam in October revealed a 2/6 systolic parasternal murmur. Echocardiogram - mild hypertrophic cardiomyopathy. Has a history of constipation, diagnosed in 2011 with severe asthma- on 2.5 mg prednisolone daily Owner notes he has occasional bowel movements in inappropriate areas

SPECIES

Feline

Abnormal PE/Chem/CBC/UA Results: From November 2022: normal CBC, CHEM: mild hypokalemia, and hypochloremia. elevated proBNP (343) creatinine 1.5, SDMA 10, USG 1.030 TT4 : 1.3

BREED

DSH

RADIOGRAPHIC STUDY OF THE THORAX & ABDOMEN

Right/left lateral and ventrodorsal whole body views totaling 3 images available for review.

RADIOGRAPHIC FINDINGS

SEX

MN

Thorax

A moderate generalized bronchial lung pattern is seen and evenly distributed throughout the lung. Mild peribronchial cuffing is noted accentuating the caudodorsal lung field. There are occasional pulmonary osteomas.

AGE

14 Years

The cardiac silhouette present within normal limits. No evidence of generalized cardiomegaly or specific chamber enlargement is noted. The vertebral heart score is 8 which is within the reference range of 8.5. No evidence of a vascular lung pattern is noted.

INTERPRETED BY

Nele Eley, DVM
 Dr. med. Vet. DipECVDI

Course and width of the trachea present within normal limits.

There is no evidence of mediastinal widening.

The thoracic boundaries present within age related normal limits.

HOSPITAL NAME

Northshore
 Veterinary Hospital

Abdomen

The abdominal serosal detail is maintained.

The stomach is postprandial. A mild amount of gravel is seen in the gastric pylorus.

REFERRING VET

Brita Kiffney

The small intestine presents within the expected limits.

A moderate amount of inspissated fecal matter is seen within the descending colon. No evidence of abnormal dilation of the descending colon is seen. However, there appears to be quite a large amount of fecal matter cranial to the pelvic inlet as well as within the pelvic canal.

INVOICE

55777

The urinary bladder is severely distended. No abnormal opacities are seen superimposed onto the urinary bladder.

DATE

12-21-22

No abnormalities of the liver are noted.

Both kidneys present within normal limits.



PATIENT

Shadow Taylor

SPECIES

Feline

BREED

DSH

SEX

MN

AGE

14 Years

INTERPRETED BY

Nele Eley, DVM
Dr. med. Vet. DipECVDI

HOSPITAL NAME

Northshore
Veterinary Hospital

REFERRING VET

Brita Kiffney

INVOICE

55777

DATE

12-21-22

RADIOGRAPHIC DIAGNOSIS

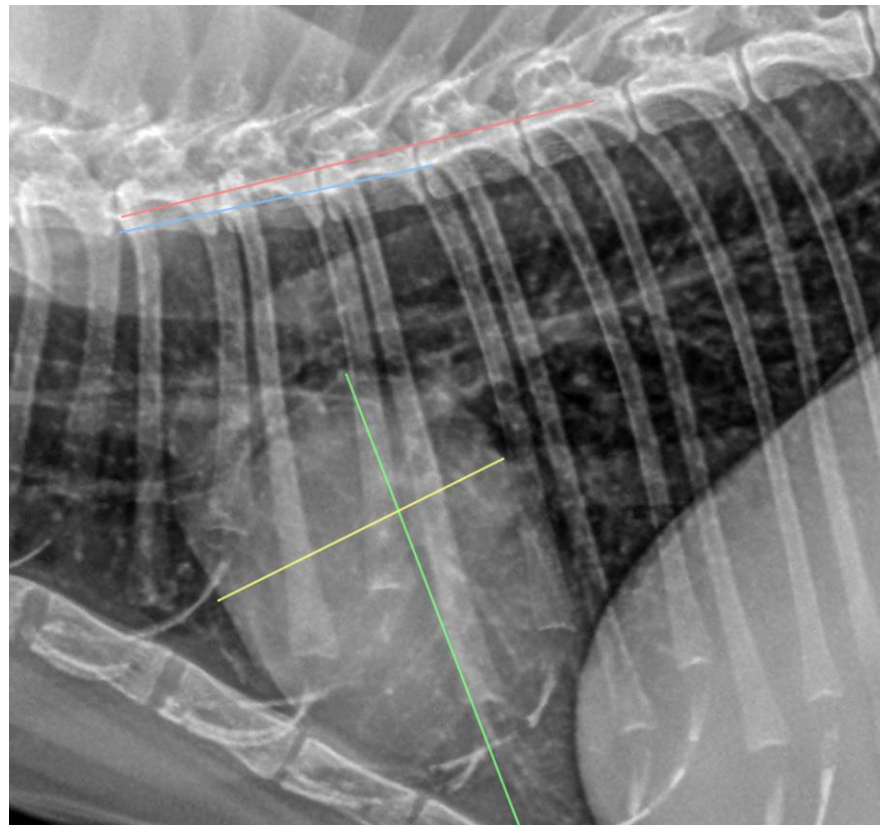
- Moderate bronchial lung pattern with no significant air trapping.
- Normal radiographic presentation of the cardiac silhouette.
- Constipation.

INTERPRETATION OF THE FINDINGS & FURTHER RECOMMENDATIONS

The radiographic findings confirm presence of a bronchial lung pattern which may be due to chronic/recurrent allergic lower airway syndrome. Infectious bronchitis such as viral, bacterial, and parasitic cannot be ruled out entirely. Further definition could be considered in case of pertinent clinical signs.

Mild to moderate constipation of the colon appears to be present with no radiographic evidence of megacolon.

The urinary bladder is severely distended with no evidence of abnormal opacities within the lower urinary system.





PATIENT

Shadow Taylor

The information and recommendations provided are based on the images presented by the referring veterinarian/sonographer. No evaluation can be communicated regarding pathology that was not visible in the image/video clips provided.

SPECIES

Feline

Thank you for this referral. If the clinical or image interpretation does not parallel your findings or if I can be of any further assistance please contact me.

BREED

DSH

Nele Eley, DVM, Dr. med. vet., DipECVDI
European Specialist in Veterinary Diagnostic Imaging, Cert. Radiology,
Senior lecturer University of Giessen, Germany, Veterinary Faculty, Department of Radiology
Nele.Eley@sonopath.com

SEX

MN

AGE

14 Years

INTERPRETED BY

Nele Eley, DVM
Dr. med. Vet. DipECVDI

HOSPITAL NAME

Northshore
Veterinary Hospital

REFERRING VET

Brita Kiffney

INVOICE

55777

DATE

12-21-22