

**PATIENT**

Romeo Rho

**PRESENTING CLINICAL SIGNS**

Patient presented for intermittent limping on right forelimb, owner did trial of metacam and did not see improvement

**SPECIES**

Canine

**RADIOGRAPHIC STUDY OF THE SHOULDERS**

Mediolateral views of both shoulders and elbows and craniocaudal view of both elbows totaling 4 images available for review.

**BREED**

Yorkshire Terrier

Shoulder region interpretation requested.

**RADIOGRAPHIC FINDINGS****SEX**

MN

The caudal contour of both humeral heads is relatively steep; however, there is no evidence of joint space incongruity between the glenoid cavity and humeral heads in either of the shoulders. No evidence of aggressive bone lesions, traumatic osseous injury, or dysplasia is seen. There is no evidence of osteoarthritis.

**AGE**

11 Years

The small osseous structure cranial of the right shoulder seen in one of the mediolateral views is likely to represent a remnant of the clavicle.

Redundancy of the dorsal tracheal ligament is seen in the cervical trachea.

**INTERPRETED BY**

Nele Eley, DVM  
Dr. med. Vet. DipECVDI

Both elbows presents mild osteoarthritic changes with evidence of medial coronoid pathology which, however, is very variable in clinical significance in toy breed dogs.

**RADIOGRAPHIC DIAGNOSIS**

- Radiographically normal age related shoulders without evidence of dysplasia, traumatic osseous injury, or aggressive bone lesions.
- Suspect dynamic tracheal disease.

**HOSPITAL NAME**

Boca Park Animal  
Hospital

**INTERPRETATION OF THE FINDINGS & FURTHER RECOMMENDATIONS**

The radiographic study of the shoulders reveals no evidence of dysplasia, osteoarthritis, aggressive bone disease, or trauma. Articular and periarticular soft tissue injury such as medial shoulder instability and other cannot be ruled out. Cervical neurologic disease is a potential consideration as well.

**REFERRING VET**

Dr. Corinna Gorgon

**INVOICE**

49177

**DATE**

12-21-21



**PATIENT**

Romeo Rho

**SPECIES**

Canine

**BREED**

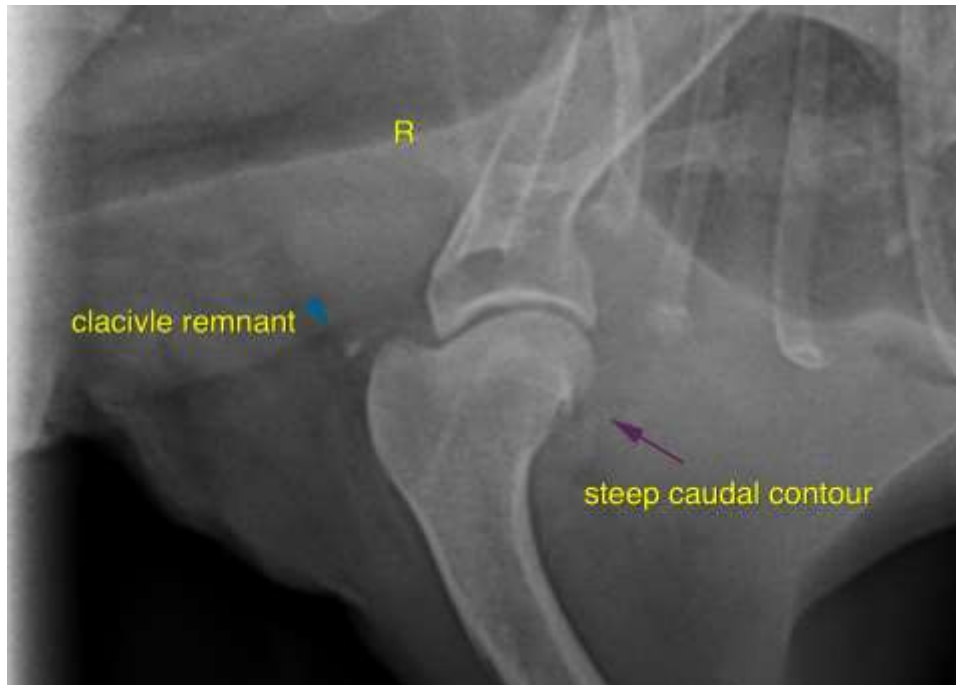
Yorkshire Terrier

**SEX**

MN

**AGE**

11 Years



**INTERPRETED BY**

Nele Eley, DVM  
Dr. med. Vet. DipECVDI

The information and recommendations provided are based on the images presented by the referring veterinarian. No evaluation can be communicated regarding pathology that was not visible in the image/video clips provided.

Thank you for this referral. If the clinical or image interpretation does not parallel your findings or if I can be of any further assistance please contact me.

**HOSPITAL NAME**

Boca Park Animal  
Hospital

**Nele Eley**, DVM, Dr. med. vet., DipECVDI  
European Specialist in Veterinary Diagnostic Imaging, Cert. Radiology,  
Senior lecturer University of Giessen, Germany, Veterinary Faculty, Department of Radiology  
Nele.Eley@sonopath.com

**REFERRING VET**

Dr. Corinna Gorgon

**INVOICE**

49177

**DATE**

12-21-21