



PATIENT

Minnie Brophy

PRESENTING CLINICAL SIGNS

Recent history of gagging/coughing(?). Was vomiting daily, now gagging at night. Keeps down breakfast, but has been vomiting dinner. Also gradual, mild, recent weight loss. History of low-grade cutaneous MCT in 2018.

SPECIES

Canine

Abnormal PE/Chem/CBC/UA Results: CBC: WNL Chem: SDMA=19 Fecal: Neg UA: USpG=1.040; pH=8.5; struvite crystals; NOSF

RADIOGRAPHIC STUDY OF THE THORAX

BREED

Boxer

Right/left lateral and ventrodorsal views totaling 3 images available for review.

RADIOGRAPHIC FINDINGS

T11/12, T13/L1, and L2/3 reveal mild spondyloses.

SEX

Female Spayed

The extrathoracic soft tissues present homogeneous without abnormalities.

The heart is of normal size and shape and there is no evidence of cardiac chamber or vascular enlargement. The pulmonary vasculature is within normal limits. The vertebral heart score is 11 which is within normal limits for a Boxer.

AGE

7 Years

The cranial mediastinum presents the expected soft tissue opacity. The mediastinal width is less than twice the width of the vertebral column at the same level.

INTERPRETED BY

Nele Eley, DVM
Dr. med. Vet. DipECVDF

The trachea is normal in diameter and presents the anticipated course. The luminal outline of the trachea is smooth.

There is a mild generalized bronchial lung pattern with even distribution throughout the lung.

HOSPITAL NAME

Long Valley Animal
Hospital

The diaphragm is well delineated with even surface and the expected mild cranial bulging of the diaphragmatic cupola.

RADIOGRAPHIC DIAGNOSIS

- Mild bronchial lung pattern.
- Mild spondyloses.
- Radiographically normal cardiac silhouette.

REFERRING VET

Russell Earl

INTERPRETATION OF THE FINDINGS & FURTHER RECOMMENDATIONS

The radiographic study reveals a mild bronchial lung pattern which may be within age related normal limits; however, chronic low grade lower airway disease such as irritant bronchitis, eosinophilic bronchopneumopathy, or infectious bronchitis cannot be ruled out entirely. Correlate with the clinical signs to determine the need for further definition by means of airway endoscopy with airway sampling.

INVOICE

49172

DATE

12-21-21



PATIENT

Minnie Brophy

SPECIES

Canine

BREED

Boxer

SEX

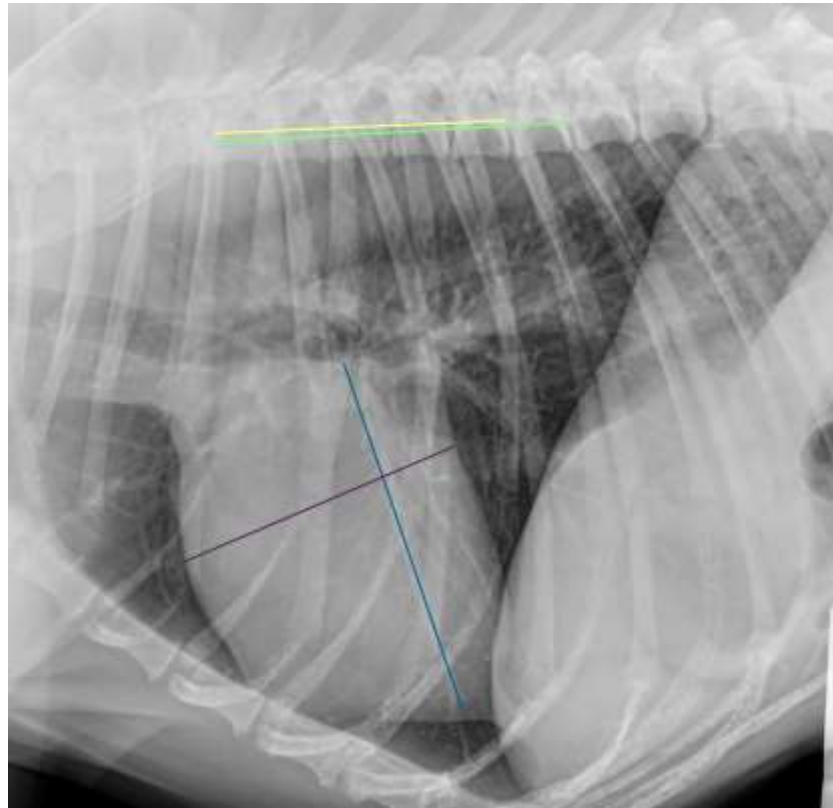
Female Spayed

AGE

7 Years

INTERPRETED BY

Nele Eley, DVM
Dr. med. Vet. DipECVDI



HOSPITAL NAME

Long Valley Animal
Hospital

REFERRING VET

Russell Earl

INVOICE

49172

DATE

12-21-21

The information and recommendations provided are based on the images presented by the referring veterinarian. No evaluation can be communicated regarding pathology that was not visible in the image/video clips provided.

Thank you for this referral. If the clinical or image interpretation does not parallel your findings or if I can be of any further assistance please contact me.

Nele Eley, DVM, Dr. med. vet., DipECVDI
European Specialist in Veterinary Diagnostic Imaging, Cert. Radiology,
Senior lecturer University of Giessen, Germany, Veterinary Faculty, Department of Radiology
Nele.Eley@sonopath.com