



**PATIENT**

Hedda Braas

**PRESENTING CLINICAL SIGNS**

left hind limb lameness - resolved with cage rest and anti-inflammatory medication  
Abnormal PE/Chem/CBC/UA Results: not performed

**SPECIES**

Canine

**COMPUTED TOMOGRAPHIC FINDINGS**

**Lumbar Spine**

Multiple intervertebral discs reveal focal mineralization.

**BREED**

Dachshund

Moderate protrusion of the lumbosacral intervertebral disc is seen.

**SEX**

Female

There is a mild amount of faintly hyperattenuating material within the ventral and left epidural space level with the caudal half of the 3<sup>rd</sup> lumbar vertebra which appears to cause a minimal mass effect onto the spinal cord.

**Hind Limbs**

The patient is obese.

**AGE**

1.5

The coxofemoral joints present within normal limits. No evidence of traumatic osseous injury is seen.

Mild motion artifact is noted level with the stifles which, however, present within age related normal limits as well. There is no evidence of patella luxation or articular swelling. The periarticular margins present even and smooth.

**INTERPRETED BY**

Nele Eley, DVM  
Dr. med. Vet. DipECVDI

The tarsal joints present within normal limits.

No evidence of structural soft tissue changes is seen in the hind limbs.

**HOSPITAL NAME**

Advanced Veterinary  
Imaging

**COMPUTED TOMOGRAPHIC DIAGNOSIS**

- Multifocal chondroid disc degeneration.
- Potential for non-compressive disc extrusion within the lumbar spine at L3/4.
- Moderate degenerative lumbosacral stenosis.

**REFERRING VET**

Eamon

**INTERPRETATION OF THE FINDINGS & FURTHER RECOMMENDATIONS**

The findings suggest potential for an acute non-compressive low volume disc extrusion within the lumbar spine between L3 and L4. A mild amount of hyperattenuating material is seen in the ventral epidural space and shifted to the left of the midline which would correlate with the patient's clinical signs.

**INVOICE**

49166

The CT study also reveals degenerative lumbosacral stenosis with moderate lumbosacral disc protrusion. Clinical significance of these CT changes varies, especially in small breed dogs.

**DATE**

12-21-21



**PATIENT**

Hedda Braas

**SPECIES**

Canine

**BREED**

Dachshund

**SEX**

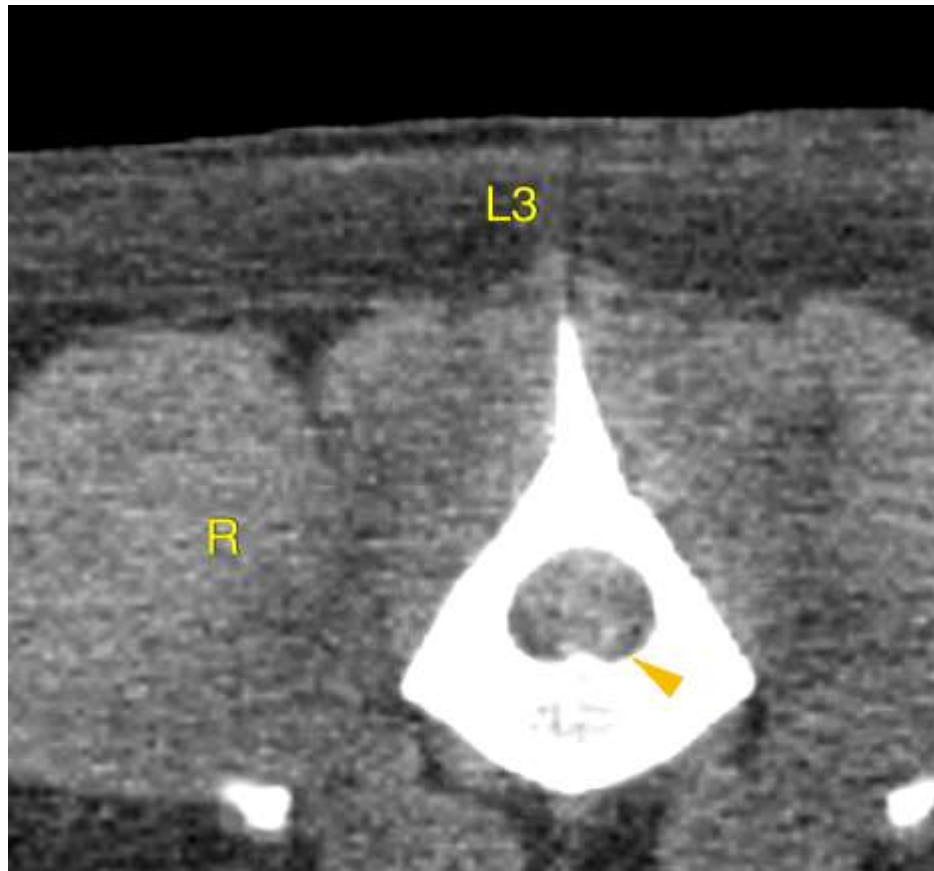
Female

**AGE**

1.5

**INTERPRETED BY**

Nele Eley, DVM  
Dr. med. Vet. DipECVDI



**HOSPITAL NAME**

Advanced Veterinary  
Imaging

**REFERRING VET**

Eamon

**INVOICE**

49166

**DATE**

12-21-21

The information and recommendations provided are based on the images presented by the referring veterinarian. No evaluation can be communicated regarding pathology that was not visible in the image/video clips provided.

Thank you for this referral. If the clinical or image interpretation does not parallel your findings or if I can be of any further assistance please contact me.

**Nele Eley**, DVM, Dr. med. vet., DipECVDI  
European Specialist in Veterinary Diagnostic Imaging, Cert. Radiology,  
Senior lecturer University of Giessen, Germany, Veterinary Faculty, Department of Radiology  
Nele.Eley@sonopath.com