



PATIENT PRESENTING CLINICAL SIGNS

Meyer Raine Presented because of a generalized seizure. Also treated chronically for cushings Neurological exam - Normal Bloodwork - Mild non regenerative anemia, mild elevation in hepatic enzymes, elevated BUN with normal creatinine CSF analysis - Normal

SPECIES MAGNETIC RESONANCE IMAGING STUDY OF THE BRAIN

Canine T2, T2-star, plain and post contrast, FLAIR, and T1-weighted, diffusion weighted with ADC images available for review.

BREED MAGNETIC RESONANCE IMAGING FINDINGS

Dachshund (min. Smooth Haired) Mild increase in pituitary gland height with 6.5mm and pituitary asymmetry with deviation of the pituitary flush are seen.

SEX There appears to be minimal generalized parenchymal atrophy with minimal generalized widening of the csf spaces.

MN The interthalamic adhesion height is within normal limits with 5.5mm. No evidence of intracranial hemorrhage and no evidence of cerebrovascular disease is found.

AGE The signal intensity and enhancement of the neuroparenchyma and meninges present within the expected limits.

13 Years A 4mm sized fat intense dermal nodule is seen on the convexity of the skull to the right of the midline.

INTERPRETED BY The caudal pole diameter of the left and right adrenal gland is approximately 9mm.

Nele Eley, DVM
Dr. med. Vet. DipECVDI

MAGNETIC RESONANCE IMAGING DIAGNOSIS

- HOSPITAL NAME**
- Mild pituitary gland enlargement and asymmetry.
 - Mild global brain atrophy – presumably within age related normal limits.
 - Fatty dermal nodule.
 - Mild bilateral adrenomegaly.

Animal Health Partners

INTERPRETATION OF THE FINDINGS & FURTHER RECOMMENDATIONS

REFERRING VET No structural cause of the seizural activity can be identified on the MRI study of the brain. The mild pituitary gland enlargement is compatible with the history of Cushing’s and pituitary adenoma. The intracranial mass effect, however, is considered minimal and unlikely to cause convulsive pathology. Late onset primary epilepsy is rare. Temporal lobe sclerosis as described in people has not been proven to exist in dogs yet. Neurodegenerative disease and microangiopathy are potential differential diagnoses. Inflammatory/infectious disease can never be ruled out entirely but appear unlikely. Complementary csf analysis could be considered if not performed already.

Dr. Greg Kilburn

INVOICE
55736

DATE
12-20-22



PATIENT

Meyer Raine

SPECIES

Canine

BREED

Dachshund (min.
Smooth Haired)

SEX

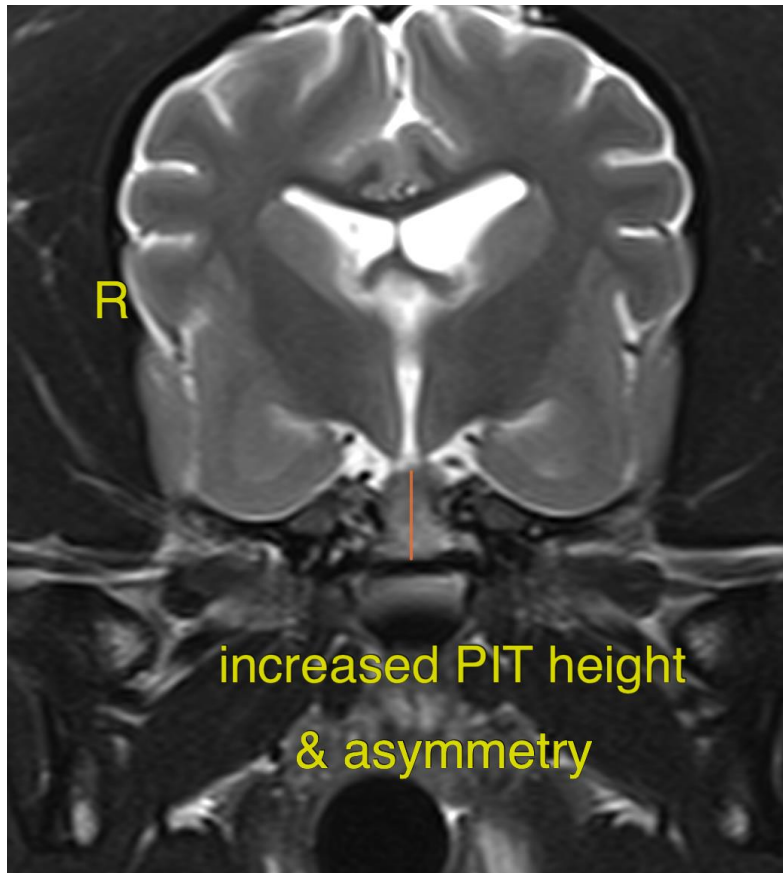
MN

AGE

13 Years

INTERPRETED BY

Nele Eley, DVM
Dr. med. Vet. DipECVDI



HOSPITAL NAME

Animal Health
Partners

REFERRING VET

Dr. Greg Kilburn

The information and recommendations provided are based on the images presented by the referring veterinarian/sonographer. No evaluation can be communicated regarding pathology that was not visible in the image/video clips provided.

Thank you for this referral. If the clinical or image interpretation does not parallel your findings or if I can be of any further assistance please contact me.

Nele Eley, DVM, Dr. med. vet., DipECVDI
European Specialist in Veterinary Diagnostic Imaging, Cert. Radiology,
Senior lecturer University of Giessen, Germany, Veterinary Faculty, Department of Radiology
Nele.Eley@sonopath.com

INVOICE

55736

DATE

12-20-22