



PATIENT

Armani Le

PRESENTING CLINICAL SIGNS

Possible partial tear in right ACL . Unable to weight bear and is limping on right hind leg after running and chasing squirrel. Clicking noise heard on manipulation.

SPECIES

Canine

RADIOGRAPHIC STUDY OF THE RIGHT STIFLE

Mediolateral view of the right stifle, ventrodorsal hip extended view of the pelvis, and mediolateral and craniocaudal views of the right tarsus totaling 9 images available for review.

BREED

Maltese

Stifle read requested.

SEX

Neutered Male

RADIOGRAPHIC FINDINGS

Moderate articular swelling of the right stifle joint is seen with no clear cranial thrust of the tibia.

There appears to be mild proximal displacement of the popliteal sesamoid bone.

A cartilage remnant is seen in the apophysis of the tibial tuberosity.

The patella is in situ.

AGE

8 Years

No significant osteoarthritic changes are seen.

The medial fabella is in a distal position which is typical in small chondrodystrophic dogs.

There is medial curvature of the proximal tibia.

No significant muscle atrophy is noted.

INTERPRETED BY

Nele Eley, DVM
Dr. med. Vet. DipECVDI

HOSPITAL NAME

Truscott Animal
Hospital

RADIOGRAPHIC DIAGNOSIS

- Moderate articular swelling of the right stifle joint with no definitive radiographic signs of cruciate ligament injury.

INTERPRETATION OF THE FINDINGS & FURTHER RECOMMENDATIONS

Cruciate ligament injury remains a potential cause of the pertinent clinical and radiographic changes in the right stifle joint. The articular swelling may represent effusion, synovial swelling, or a combination of these. Post-traumatic arthropathy and arthritis including immune mediated (and tickborne) are potential differential diagnoses next to cruciate ligament pathology and meniscopathy. Correlation with the clinical palpation required. Aspiration and analysis of synovia could be considered should this remain inconclusive, and an MRI of the stifle joint could be considered in order to further assess for cruciate ligament injury and/or meniscopathy.

REFERRING VET

Dr. Medhat Meawad

INVOICE

55755

DATE

12-20-22



PATIENT

Armani Le

SPECIES

Canine

BREED

Maltese

SEX

Neutered Male

AGE

8 Years

INTERPRETED BY

Nele Eley, DVM
Dr. med. Vet. DipECVDI

HOSPITAL NAME

Truscott Animal
Hospital

REFERRING VET

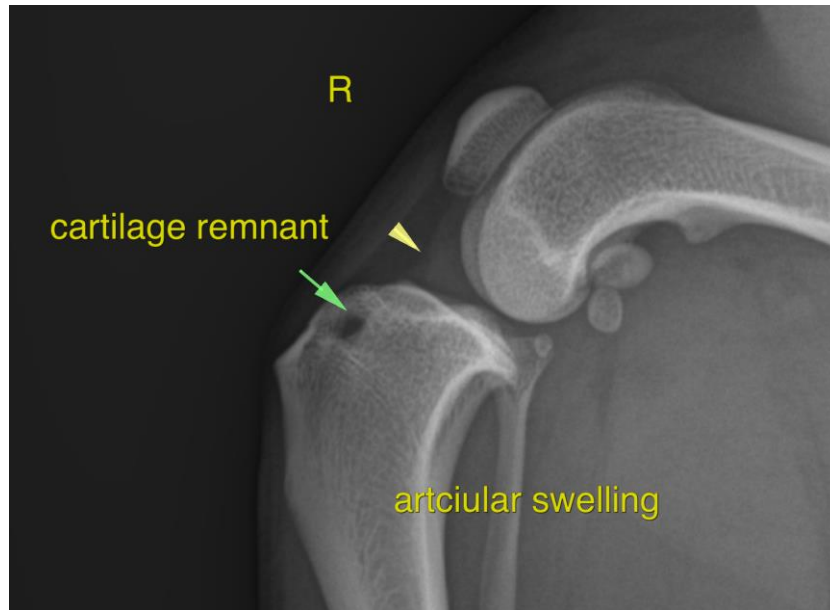
Dr. Medhat Meawad

INVOICE

55755

DATE

12-20-22



The information and recommendations provided are based on the images presented by the referring veterinarian/sonographer. No evaluation can be communicated regarding pathology that was not visible in the image/video clips provided.

Thank you for this referral. If the clinical or image interpretation does not parallel your findings or if I can be of any further assistance please contact me.

Nele Eley, DVM, Dr. med. vet., DipECVDI
European Specialist in Veterinary Diagnostic Imaging, Cert. Radiology,
Senior lecturer University of Giessen, Germany, Veterinary Faculty, Department of Radiology
Nele.Eley@sonopath.com