

**PATIENT PRESENTING CLINICAL SIGNS**

Andy Walker Intermittent lameness on right hind leg that temporally responds to anti-inflammatory. Crepitus right hind leg.
Abnormal PE/Chem/CBC/UA Results: Ambulatory x 4. No lameness appreciated prior to CT.

SPECIES COMPUTED TOMOGRAPHIC STUDY OF THE STIFLES

Canine Plain and post IV contrast studies of the stifles available for review.

BREED COMPUTED TOMOGRAPHIC FINDINGS

Greyhound The right and left stifle present within normal limits in the CT study. There is no evidence of articular enlargement or effusion. The cranial and caudal cruciate ligament are seen and appear to be continuous. Meniscomfemoral ligament presents within normal limits. No evidence of subchondral bone defects or articular margin remodeling is noted. The fabellae are in situ and within normal limits. The patella is in situ. The popliteal sesamoid bone presents within the expected limits and the long digital extensor presents within normal limits as well.

SEX

Neutered Male

The left stifle reveals no structural abnormality.

AGE

No significant muscle atrophy can be identified in the right hind limb.

4 Years, 2 Months

COMPUTED TOMOGRAPHIC DIAGNOSIS

- Normal CT findings of both stifles.

INTERPRETED BY

Nele Eley (Ondreka),
DVM Dr. med. vet.,
DipECVDI

INTERPRETATION OF FINDINGS & FURTHER RECOMMENDATIONS

The CT study does not reveal evidence of effusion or other signs of arthropathy of the right stifle joint. Obviously emerging edema or partial fiber disintegration of the cranial cruciate ligament can never be ruled out entirely. However, it would be very atypical with the current CT presentation to have a case of cruciate ligament pathology, meniscopathy, or other arthropathy.

HOSPITAL NAME

Mobile Pet Imaging

REFERRING VET

Meaux

INVOICE

55731

DATE

12-20-22



PATIENT

Andy Walker

SPECIES

Canine

BREED

Greyhound

SEX

Neutered Male

AGE

4 Years, 2 Months

INTERPRETED BY

Nele Eley (Ondreka),
DVM Dr. med. vet.,
DipECVDI

HOSPITAL NAME

Mobile Pet Imaging

REFERRING VET

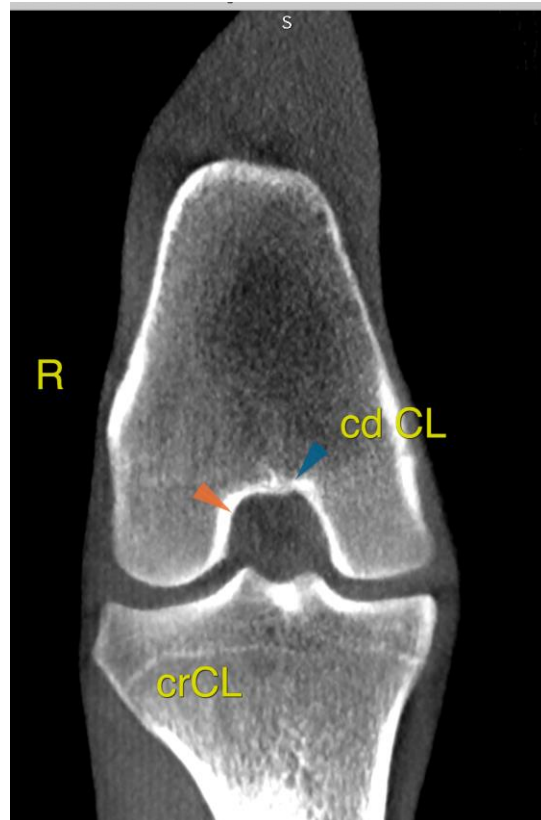
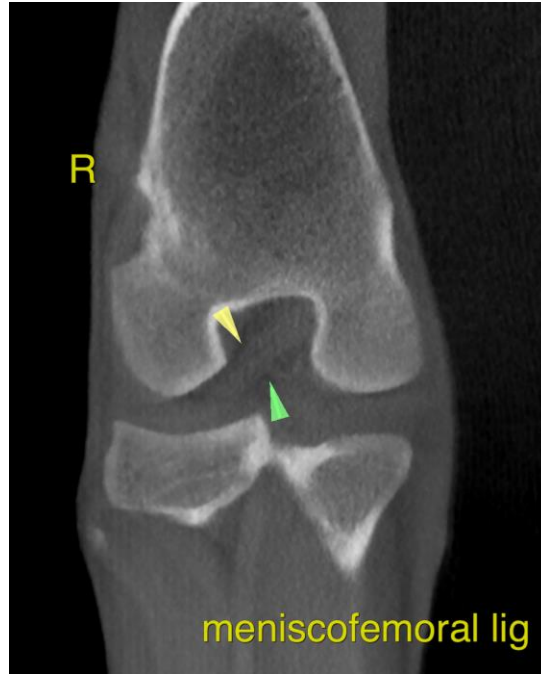
Meaux

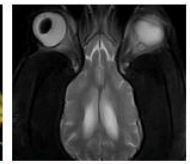
INVOICE

55731

DATE

12-20-22



**PATIENT**

Andy Walker

The information and recommendations provided are based on the images presented by the referring veterinarian. No evaluation can be communicated regarding pathology that was not visible in the image/video clips provided.

SPECIES

Canine

Thank you for this referral. If the clinical or image interpretation does not parallel your findings or if I can be of any further assistance please contact me.

BREED

Greyhound

Nele Eley (Ondreka), DVM, Dr. med. vet., DipECVDI
European Specialist in Veterinary Diagnostic Imaging, Cert. Radiology,
Senior lecturer University of Giessen/Germany, Veterinary Faculty, Department of Radiology.
Nele.Eley@sonopath.com

SEX

Neutered Male

AGE

4 Years, 2 Months

INTERPRETED BY

Nele Eley (Ondreka),
DVM Dr. med. vet.,
DipECVDI

HOSPITAL NAME

Mobile Pet Imaging

REFERRING VET

Meaux

INVOICE

55731

DATE

12-20-22