

**PATIENT**

Tyrion Robling

**PRESENTING CLINICAL SIGNS**

febrile since yesterday. P was acting normal yesterday but started getting lethargic last night. O took P temp and it was 105.7. She was able to get the temp down by feeding and getting P to drink and it came down to 104.2. P was 105.9 today. Carpi are swollen and P is walking with kyphotic posture, stiff/stilted gait with decreased stride length.

**SPECIES**

Canine

**RADIOGRAPHIC STUDY OF THE FOREARMS & STIFLES**

Mediolateral views of forearms, craniocaudal views of both carpi, and mediolateral views of both stifles totaling 5 images available for review.

**BREED**

Mastiff

**RADIOGRAPHIC FINDINGS**

Radiolucent lines are seen in the metaphyseal portions of all long bones paralleling the growth plates. Mild multifocal regional soft tissue swelling is seen as well.

**SEX**

Male

The cranial contour of the medial coronoid processes is slightly ill-defined in its proximal aspect in both elbows.

**AGE**

5 Months

No evidence of articular abnormality of the stifle joints is seen.

**RADIOGRAPHIC DIAGNOSIS**

- Polyostotic osteopathy with hyperlucencies in the metaphyseal hypertrophic zones.
- Incomplete mineralization of the medial coronoid processes of the elbows.

**INTERPRETED BY**

Nele Eley, DVM  
Dr. med. Vet. DipECVDI

**INTERPRETATION OF THE FINDINGS & FURTHER RECOMMENDATIONS**

The radiographic findings are typical for hypertrophic osteodystrophy which also explains the patient being febrile. No evidence of arthropathy of the stifle joints was seen.

**HOSPITAL NAME**

All Creatures Animal  
Hospital of South Hill,  
Inc.

The incomplete mineralization of the medial coronoid processes of the elbows may well be within age related normal limits. Consider clinical and radiographic rechecks in 2 months.

**REFERRING VET**

Dr. Preston

**INVOICE**

49160

**DATE**

12-20-21



**PATIENT**

Tyrion Robling

**SPECIES**

Canine

**BREED**

Mastiff

**SEX**

Male

**AGE**

5 Months

**INTERPRETED BY**

Nele Eley, DVM  
Dr. med. Vet. DipECVDI

**HOSPITAL NAME**

All Creatures Animal  
Hospital of South Hill,  
Inc.

**REFERRING VET**

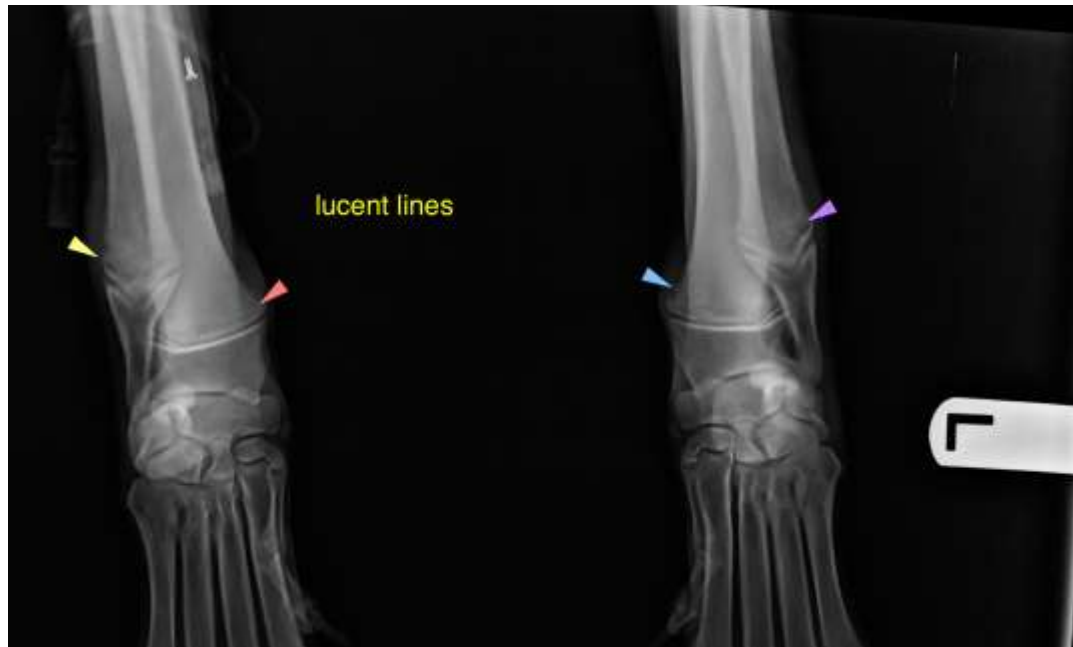
Dr. Preston

**INVOICE**

49160

**DATE**

12-20-21



The information and recommendations provided are based on the images presented by the referring veterinarian. No evaluation can be communicated regarding pathology that was not visible in the image/video clips provided.

Thank you for this referral. If the clinical or image interpretation does not parallel your findings or if I can be of any further assistance please contact me.

**Nele Eley**, DVM, Dr. med. vet., DipECVDI  
European Specialist in Veterinary Diagnostic Imaging, Cert. Radiology,  
Senior lecturer University of Giessen, Germany, Veterinary Faculty, Department of Radiology  
Nele.Eley@sonopath.com