



PATIENT

Roxy Sanders

SPECIES

Canine

BREED

Boxer Mix

SEX

Female Spayed

AGE

7Y

WEIGHT

65lbs

INTERPRETED BY

Nele Eley (Ondreka),
DVM Dr. med. vet.,
DipECVDI

IMAGING PERFORMED BY

Justeene Marquez

HOSPITAL NAME

Petroglyph Animal
Hospital

REFERRING VET

Whitney Jones

INVOICE

72818

DATE

12-2-25

PRESENTING CLINICAL SIGNS

Patient presents for dental procedure, noted during dental there was a firm gingival mass around 208; extracted 208,209,210. Submitted gingival mass for biopsy and results returned consistent with oral fibrosarcoma. Submitting CT to assess extent of invasion into bone.

Abnormal PE/Chem/CBC/UA Results: Reticulocytes 149k, chemistry WN prior to dental procedure

COMPUTED TOMOGRAPHIC STUDY OF THE DENTAL ARCADES

Plain study available for review.

COMPUTED TOMOGRAPHIC FINDINGS

An irregular shaped and ill-defined soft tissue attenuating mass is seen laterally adjacent to the left caudal maxilla. Permeative aggressive osteolysis, expansion of the lateral compact bone, and amorphous periosteal new bone formation of the left caudal maxilla are seen laterally. The involvement spans from the mesial root of the 208 to the distal root of the 209 over a distance of approximately 28mm. Extension of the aggressive osteolytic changes into the bone from the lateral aspect is approximately 5mm. No evidence of extension into the nasal cavity or orbit is seen. The zygomatic arch appears to be spared.

COMPUTED TOMOGRAPHIC DIAGNOSIS

- Oral fibrosarcoma with aggressive osteolysis of the left caudal maxilla.

INTERPRETATION OF FINDINGS & FURTHER RECOMMENDATIONS

The findings are consistent with local bone invasion of the gingival fibrosarcoma. The lesion is confined to the alveolar bone of the left caudal maxilla without extension into the nasal cavity or orbit. No other cranial structures are affected. Surgical excision with appropriate margins considering the osseous involvement can be considered after completion of the staging.



PATIENT

Roxy Sanders

SPECIES

Canine

BREED

Boxer Mix

SEX

Female Spayed

AGE

7Y

WEIGHT

65lbs

INTERPRETED BY

Nele Eley (Ondreka),
DVM Dr. med. vet.,
DipECVDI

IMAGING PERFORMED BY

Justeene Marquez

HOSPITAL NAME

Petroglyph Animal
Hospital

REFERRING VET

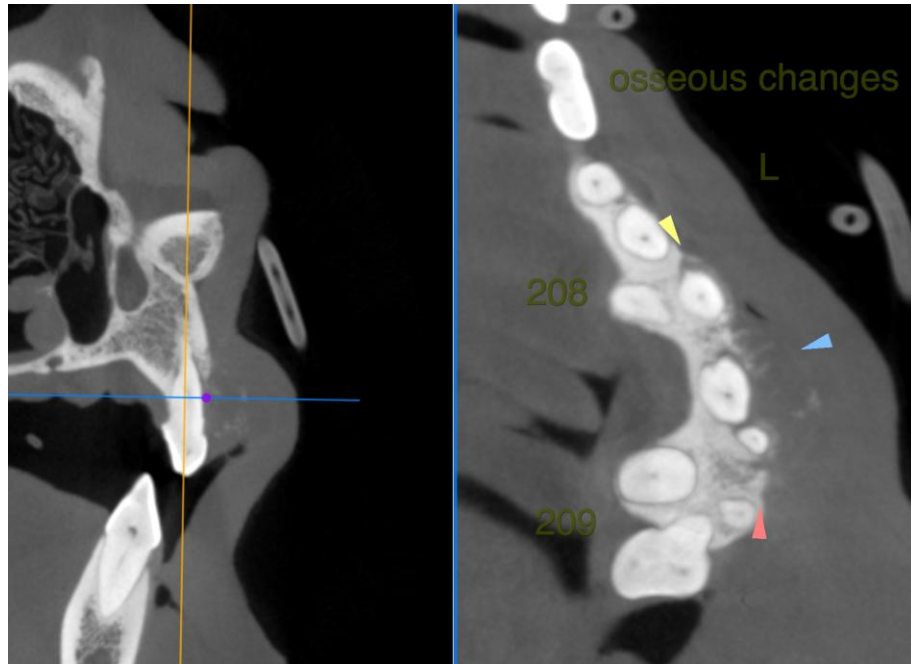
Whitney Jones

INVOICE

72818

DATE

12-2-25



The information and recommendations provided are based on the images presented by the referring veterinarian. No evaluation can be communicated regarding pathology that was not visible in the image/video clips provided.

Thank you for this referral. If the clinical or image interpretation does not parallel your findings or if I can be of any further assistance please contact me.

Nele Eley (Ondreka), DVM, Dr. med. vet., DipECVDI
European Specialist in Veterinary Diagnostic Imaging, Cert. Radiology,
Senior lecturer University of Giessen/Germany, Veterinary Faculty, Department of Radiology.
info@sonopath.com