



PATIENT

Luna Vart

SPECIES

Canine

BREED

Pekingese

SEX

FS

AGE

11Y, 6M

WEIGHT

12.81lbs

INTERPRETED BY

Nele Eley (Ondreka),
DVM Dr. med. vet.,
DipECVDI

IMAGING PERFORMED BY

JL/MF

HOSPITAL NAME

The Pet Hospital of
Stratford

REFERRING VET

Dr. Robert Bashkin

INVOICE

72819

DATE

12-2-25

PRESENTING CLINICAL SIGNS

Patient has been hacking up fur balls past few years. Decrease appetite, and lethargy past few weeks.

RADIOGRAPHIC STUDY OF THE ABDOMEN

Right/left lateral and ventrodorsal views of the abdomen totaling 3 images available for review.

RADIOGRAPHIC FINDINGS

The abdominal serosal detail appears to be maintained.

The stomach contains gas and a small amount of granular material, likely ingesta.

The descending duodenum shows a rigid central gas column. Small intestinal loops are nondilated.

The colon is mostly empty.

There is no radiographic evidence of a foreign body, obstruction, or mass.

RADIOGRAPHIC DIAGNOSIS

- Mild gastric retention with ingesta and gas.
- No evidence of small intestinal obstruction or other acute abdominal pathology.

INTERPRETATION OF FINDINGS & FURTHER RECOMMENDATIONS

The findings are consistent with mild gastric stasis which may correlate with the patient's chronic hairball regurgitation. The rigid appearance of the descending duodenum is noted but not associated with dilation suggesting a functional or transient change rather than mechanical obstruction. While the radiographs do not demonstrate acute obstruction, masses, or gross inflammation, gastroenteritis or pancreatitis cannot be fully excluded particularly if clinical signs persist. Gastritis, inflammatory bowel disease, or mild pancreatitis may produce some changes not evident on radiographs. Consider supportive management for hairball prevention, monitor appetite, and potential vomiting/regurgitation frequency. Consider abdominal ultrasound if clinical signs persist or laboratory abnormalities develop to assess the pancreas, gastric wall and small intestine more sensitively.



PATIENT

Luna Vart

SPECIES

Canine

BREED

Pekingese

SEX

FS

AGE

11Y, 6M

WEIGHT

12.81lbs

INTERPRETED BY

Nele Eley (Ondreka),
DVM Dr. med. vet.,
DipECVDI

IMAGING PERFORMED BY

JL/MF

HOSPITAL NAME

The Pet Hospital of
Stratford

REFERRING VET

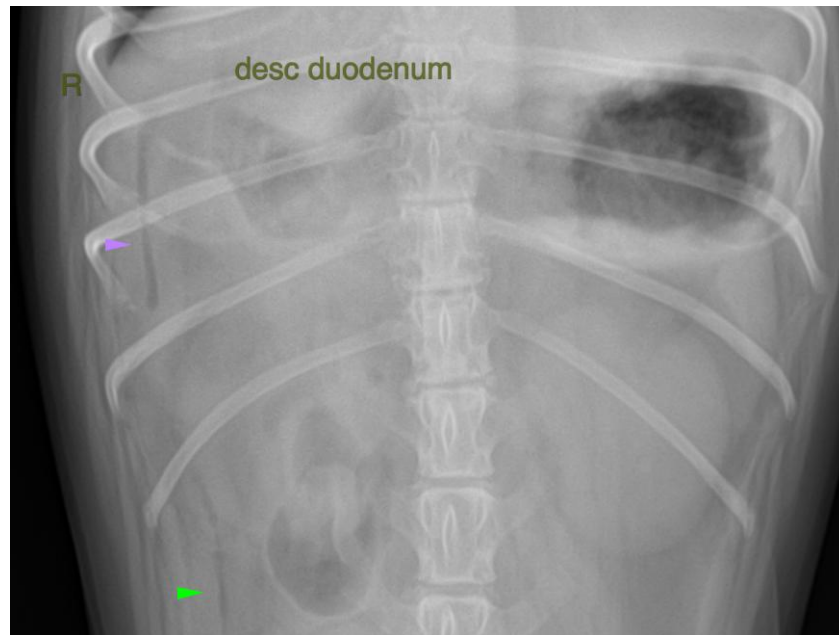
Dr. Robert Bashkin

INVOICE

72819

DATE

12-2-25



The information and recommendations provided are based on the images presented by the referring veterinarian. No evaluation can be communicated regarding pathology that was not visible in the image/video clips provided.

Thank you for this referral. If the clinical or image interpretation does not parallel your findings or if I can be of any further assistance please contact me.

Nele Eley (Ondreka), DVM, Dr. med. vet., DipECVDI
European Specialist in Veterinary Diagnostic Imaging, Cert. Radiology,
Senior lecturer University of Giessen/Germany, Veterinary Faculty, Department of Radiology.
info@sonopath.com