


**PATIENT PRESENTING CLINICAL SIGNS**

Sidney Shaw Please compare to previous radiographs obtained in October for coughing. P had a round of Doxycycline as well as Clavamox, and neither helped. O reports only thing that has helped are Cough tablets.

**SPECIES RADIOGRAPHIC STUDY OF THE THORAX**

Canine Right and left lateral and ventrodorsal views of the thorax available for reviewed compared to prior study dated 10/22/22.

**BREED RADIOGRAPHIC FINDINGS**

Terrier X A stable, moderate generalized bronchointerstitial lung pattern with peribronchial cuffing is seen. The vertebral heart score is stable at 9.9 as well. The radiographic presentation of the cardiac silhouette and pulmonary vasculature is stationary and within normal limits.

**SEX**

Spayed Female Course and width of the trachea are considered within normal limits. Mild esophageal aerophagia and mild gastric aerophagia are noted.

**AGE**

There is no evidence of mediastinal widening.

7 Years

**RADIOGRAPHIC DIAGNOSIS**

- Stationary moderate generalized chronic bronchointerstitial lung pattern

**INTERPRETED BY**

Nele Eley (Ondreka),  
 DVM Dr. med. vet.,  
 DipECVDI

**INTERPRETATION OF FINDINGS & FURTHER RECOMMENDATIONS**

The radiographic findings are stable between the prior and recent studies. Taking the antimicrobial treatment in the recent past into account, the stable radiographic findings further support the suspicion of either eosinophilic/allergic bronchopneumopathy or parasitic lung disease. Proactive deworming and anti-allergy medication could be considered in terms of a clinical trial, should airway endoscopy with airway sampling not be an option in this patient.

**HOSPITAL NAME**

The Pet Hospital of  
 Stratford

**REFERRING VET**

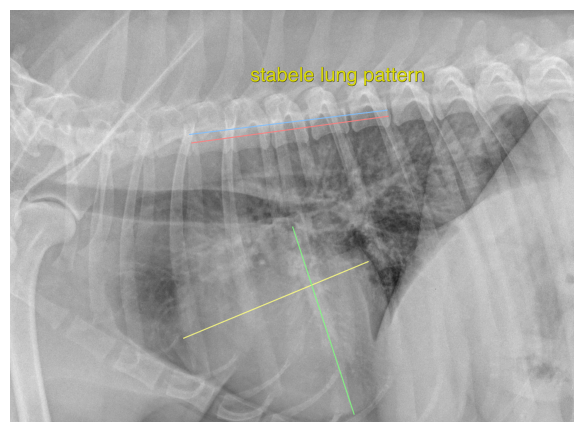
Dr. Claudia Giuliani

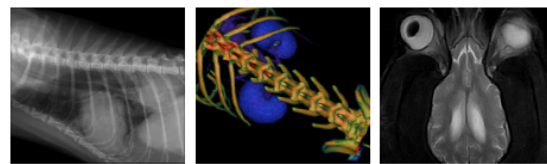
**INVOICE**

43190

**DATE**

12/2/22





**PATIENT**

Sidney Shaw

The information and recommendations provided are based on the images presented by the referring veterinarian. No evaluation can be communicated regarding pathology that was not visible in the image/video clips provided.

**SPECIES**

Canine

Thank you for this referral. If the clinical or image interpretation does not parallel your findings or if I can be of any further assistance please contact me.

**BREED**

Terrier X

**Nele Eley (Ondreka)**, DVM, Dr. med. vet., DipECVDI  
European Specialist in Veterinary Diagnostic Imaging, Cert. Radiology,  
Senior lecturer University of Giessen/Germany, Veterinary Faculty, Department of Radiology.  
Nele.Eley@sonopath.com

**SEX**

Spayed Female

**AGE**

7 Years

**INTERPRETED BY**

Nele Eley (Ondreka),  
DVM Dr. med. vet.,  
DipECVDI

**HOSPITAL NAME**

The Pet Hospital of  
Stratford

**REFERRING VET**

Dr. Claudia Giuliani

**INVOICE**

43190

**DATE**

12/2/22