


PATIENT PRESENTING CLINICAL SIGNS

Gitzy Vance Increasing episodes of soft stools with hind limb weakness - P will completely sink to the ground. During these episodes P also has a subtle change in mentation. Previous rads revealed 2 bee bee pellets in the chest/neck area. P ambulatory without lameness. ZERO neurologic deficits.

SPECIES RADIOGRAPHIC STUDY OF THE ABDOMEN

Canine Right and left lateral and ventrodorsal views of the abdomen provided for review, totaling 4 images.

BREED RADIOGRAPHIC FINDINGS

Rat Terrier Thoracolumbar and lumbosacral transitional vertebrae are noted. The thoracolumbar vertebrae are asymmetric with a right-sided vestigial rib and left-sided transverse process. Collapsed intervertebral disc spaces are seen between the last thoracic and thoracolumbar transitional vertebra as well as between the thoracolumbar transitional vertebra and the first lumbar vertebra. Vertebral endplate sclerosis and spondylosis deformans are noted concurrently. The vertebral endplate sclerosis and spondylosis deformans are present between L1/2, L2/3, L3/4 as well. There also is intervertebral disc space collapse between L2/3 and L3/4.

SEX

Spayed Female

AGE

16 Years

The coxofemoral joints present within normal limits.

A small, rectangular, metal opaque structure is seen within the mid abdomen and superimposed onto a small intestinal loop on all available images. There appears to be a mild amount of grainy, mineral opaque material in the region of the gastric outlet. The small intestinal loops are of even diameter with no evidence of abnormal dilation or plication. There is no evidence of reduced serosal detail. The small intestinal loops are mildly turgid in appearance.

INTERPRETED BY

Nele Eley (Ondreka),
 DVM Dr. med. vet.,
 DipECVDI

A single mineralization is superimposed onto the left kidney.

RADIOGRAPHIC DIAGNOSIS

- Small intestinal maldigestion pattern
- Mineralization of the left kidney
- Mild amount of gastric gravel
- Multiple sites of chronic intervertebral disc disease with multiple spondyloses
- Thoracolumbar and lumbosacral transitional vertebrae

HOSPITAL NAME

DTLAvets

REFERRING VET INTERPRETATION OF FINDINGS & FURTHER RECOMMENDATIONS

Dr. Castaneda The radiographic study reveals a small intestinal maldigestion pattern with no evidence of mechanical ileus. Functional ileus remains a potential. The metal opaque structure seen in the mid abdomen is likely to be localized within the small intestine with no evidence of obstructive ileus. This structure should pass naturally. A mild amount of gastric gravel is present without evidence of gastric dilation and considered of uncertain to no clinical significance.

INVOICE

43188

The renal mineralization may represent a calculus or dystrophic mineralization. Clinical significance is uncertain.

DATE

12/2/22

Note the presence of radiographic signs of multiple chronic intervertebral disc disease, which may be concurred by disc hernia.



PATIENT

Gitzy Vance

At this point, the clinical examination does not appear to provide any evidence of neurologic deficits. In case of further deterioration of the neurological status, an MRI or CT of the spine could be considered for further definition.

SPECIES

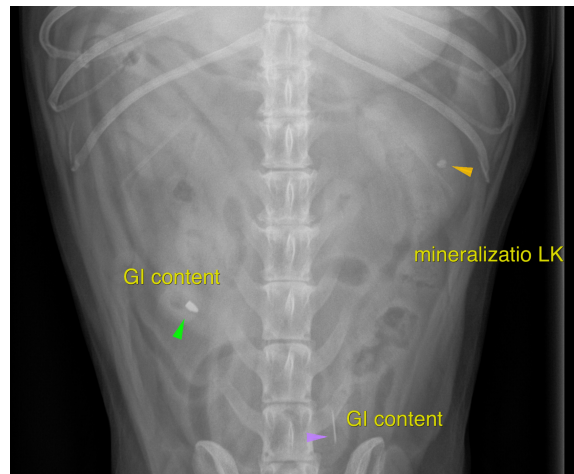
Canine

BREED

Rat Terrier

SEX

Spayed Female



AGE

16 Years

The information and recommendations provided are based on the images presented by the referring veterinarian. No evaluation can be communicated regarding pathology that was not visible in the image/video clips provided.

INTERPRETED BY

Nele Eley (Ondreka),
DVM Dr. med. vet.,
DipECVDI

Thank you for this referral. If the clinical or image interpretation does not parallel your findings or if I can be of any further assistance please contact me.

Nele Eley (Ondreka), DVM, Dr. med. vet., DipECVDI
European Specialist in Veterinary Diagnostic Imaging, Cert. Radiology,
Senior lecturer University of Giessen/Germany, Veterinary Faculty, Department of Radiology.
Nele.Eley@sonopath.com

HOSPITAL NAME

DTLAvets

REFERRING VET

Dr. Castaneda

INVOICE

43188

DATE

12/2/22