

**PATIENT**

Cheese Ho

PRESENTING CLINICAL SIGNS

Complex epileptic seizures and hepatopathy. Possible facial twitches intermittently over the past year, changes in behaviour, more severe episodes, and visible post-ictal phase over the past week

SPECIES

Canine

MAGNETIC RESONANCE IMAGING STUDY OF THE BRAIN

T2, T2-star, diffusion weighted, FLAIR, and T1-plain and post contrast studies in variable image planes available for review.

BREED

Chihuahua

MAGNETIC RESONANCE IMAGING FINDINGS

The patient is a brachycephalic head type.

SEX

FS

Mild foraminal herniation of the cerebellum is seen. The lateral and third ventricles are mildly enlarged. A small supracollicular fluid accumulation is seen.

AGE

3 Years

MAGNETIC RESONANCE IMAGING DIAGNOSIS

- Bilateral diffuse hippocampal and temporal lobe hyperintensity with increased perfusion.

INTERPRETED BY

Nele Eley, DVM
Dr. med. Vet. DipECVDI

INTERPRETATION OF THE FINDINGS & FURTHER RECOMMENDATIONS

The MRI study reveals symmetric diffuse encephalopathy with hyperintensity and increase perfusion of both the hippocampus and temporal lobes. The changes may simply reflect postictal edema; however, immune mediated encephalitis similar to human limbic encephalitis and FEPSO is a potential differential diagnosis. Hippocampal necrosis and temporal lobe necrosis can develop secondary to cluster seizures. However, this seems very unlikely in this case owing to the maintained and even increased perfusion in the affected areas. No evidence of manganese deposition in the lentiform nucleus is noted.

HOSPITAL NAME

Animal Health
Partners

REFERRING VET

Dr. Marchal

INVOICE

48756

DATE

12-2-21



PATIENT

Cheese Ho

SPECIES

Canine

BREED

Chihuahua

SEX

FS

AGE

3 Years

INTERPRETED BY

Nele Eley, DVM
Dr. med. Vet. DipECVDI

HOSPITAL NAME

Animal Health
Partners

REFERRING VET

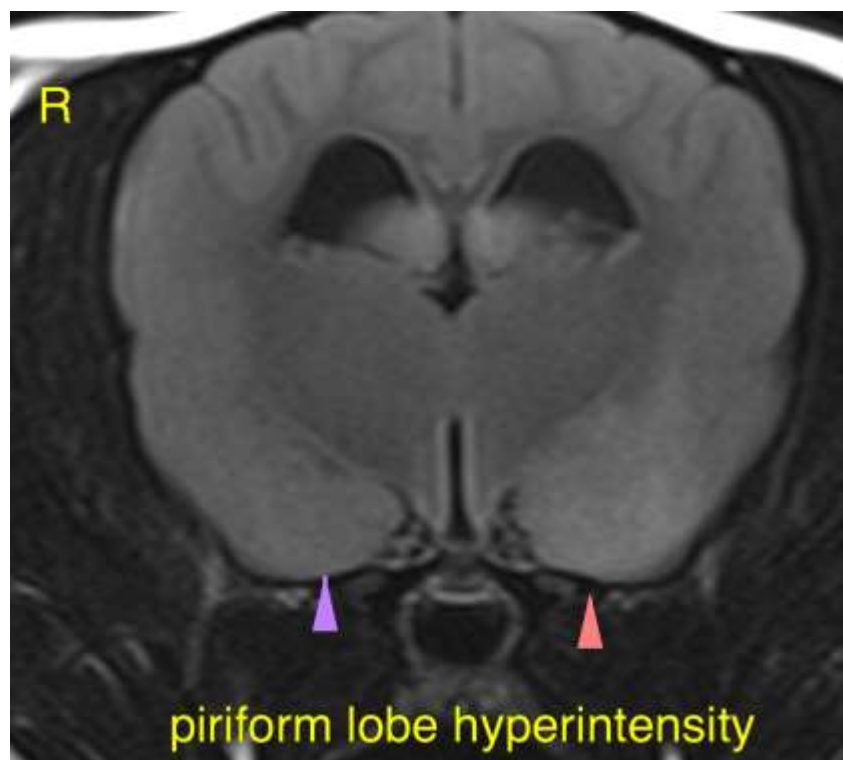
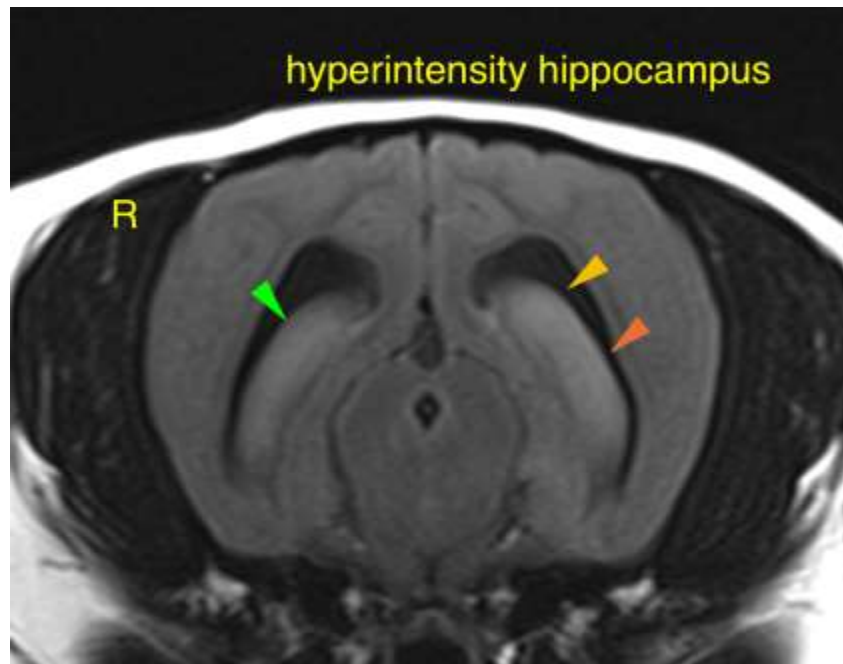
Dr. Marchal

INVOICE

48756

DATE

12-2-21





PATIENT

Cheese Ho

SPECIES

Canine

BREED

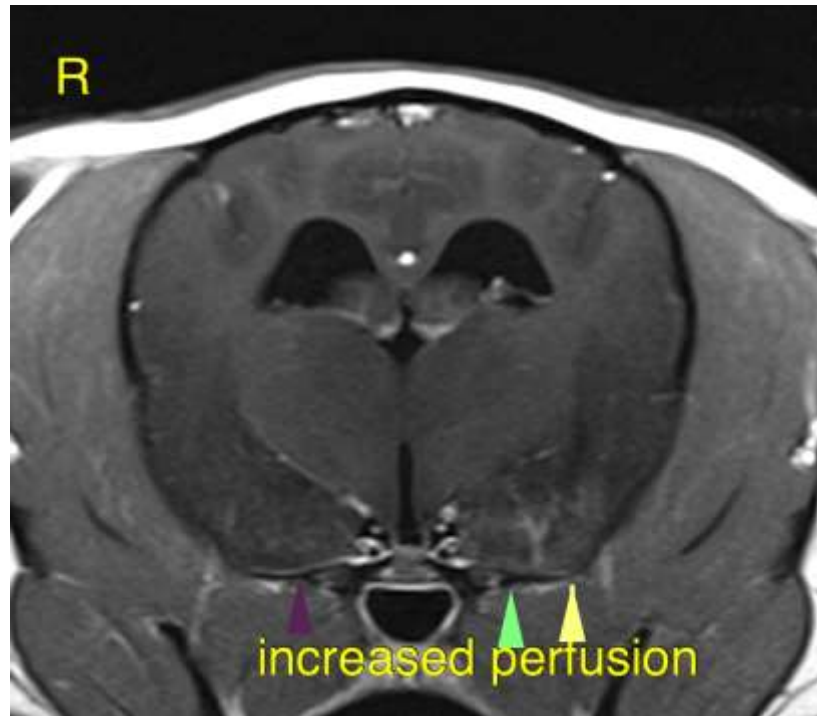
Chihuahua

SEX

FS

AGE

3 Years



INTERPRETED BY

Nele Eley, DVM
Dr. med. Vet. DipECVDI

HOSPITAL NAME

Animal Health
Partners

REFERRING VET

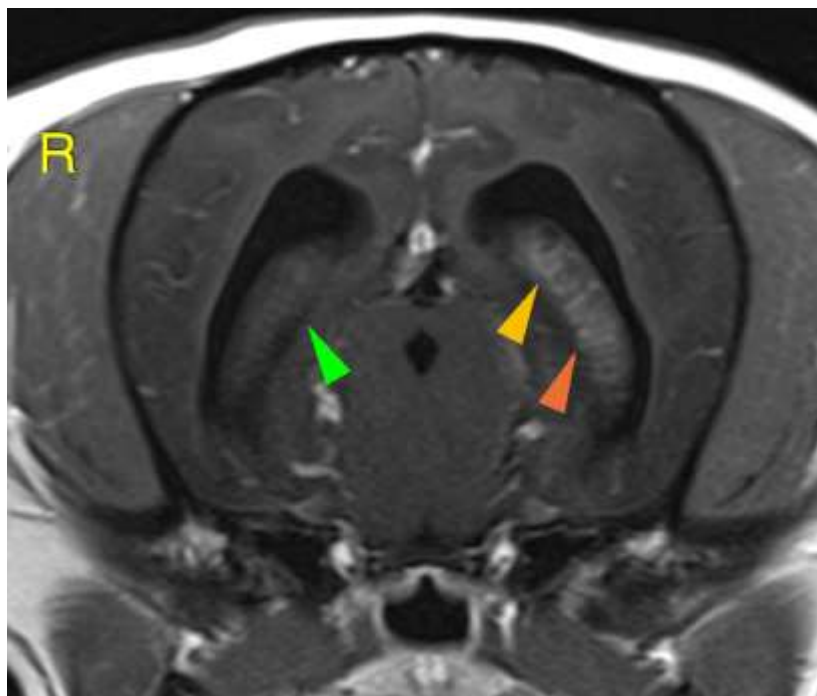
Dr. Marchal

INVOICE

48756

DATE

12-2-21





PATIENT

Cheese Ho

The information and recommendations provided are based on the images presented by the referring veterinarian. No evaluation can be communicated regarding pathology that was not visible in the image/video clips provided.

Thank you for this referral. If the clinical or image interpretation does not parallel your findings or if I can be of any further assistance please contact me.

SPECIES

Canine

Nele Eley, DVM, Dr. med. vet., DipECVDI
European Specialist in Veterinary Diagnostic Imaging, Cert. Radiology,
Senior lecturer University of Giessen, Germany, Veterinary Faculty, Department of Radiology
Nele.Eley@sonopath.com

BREED

Chihuahua

SEX

FS

AGE

3 Years

INTERPRETED BY

Nele Eley, DVM
Dr. med. Vet. DipECVDI

HOSPITAL NAME

Animal Health
Partners

REFERRING VET

Dr. Marchal

INVOICE

48756

DATE

12-2-21