



PATIENT

Tiutia Dewitt

PRESENTING CLINICAL SIGNS

O noticed a quarter-sized mass in P's right armpit and elected to remove it. Pre mass removal scan to observe if there is any metastasis

SPECIES

Canine

COMPUTED TOMOGRAPHIC STUDY OF THE THORAX & ABDOMEN

Plain study of the thorax and plain and post contrast studies of the thorax and abdomen available for review.

BREED

Caucasian Shepherd
Dog

COMPUTED TOMOGRAPHIC FINDINGS

The patient is obese.

An approximately 1 x 2 cm sized uniformly fat attenuating nodule is seen in the right armpit.

SEX

FS

Thorax

The sternal, cranial mediastinal and tracheobronchial lymph nodes are small elongated with a normal short-to-long-axis-ratio is < 0.5.

AGE

7 Years

The cardiovascular structures including the pulmonary vasculature are within normal limits.

The bronchial tree presents with regular branching and tapers uniformly towards the periphery as expected, the bronchial walls are thin and smooth. The bronchus-to-artery ratio is within normal limits.

INTERPRETED BY

Nele Eley, DVM
Dr. med. Vet. DipECVDI

The lung parenchyma presents the expected architecture and attenuation behavior.

Small incidental gas pockets are seen within the esophageal lumen, there is no evidence of abnormal dilation.

HOSPITAL NAME

Catskill Veterinary
Services, PLLC

Abdomen

Moderate T12/13, L2/3, L3/4 spondylosis deformans are seen.

Moderate protrusion of the lumbosacral intervertebral disc is noted with early spondylosis deformans.

REFERRING VET

Dr. Daniela Carbone

The coxofemoral joints present mild osteoarthritic changes.

Occasional hyperenhancing nodules are seen in the spleen.

INVOICE

55715

An old cortical renal infarct is seen in the right kidney.

Faintly hyperenhancing nodules are present within the liver.

A 9mm sized slightly hypoenhancing nodule is seen in the caudal pole of the left adrenal gland.

DATE

12-19-22



PATIENT

Tiutia Dewitt

SPECIES

Canine

BREED

Caucasian Shepherd
Dog

SEX

FS

AGE

7 Years

INTERPRETED BY

Nele Eley, DVM
Dr. med. Vet. DipECVDI

HOSPITAL NAME

Catskill Veterinary
Services, PLLC

REFERRING VET

Dr. Daniela Carbone

INVOICE

55715

DATE

12-19-22

COMPUTED TOMOGRAPHIC DIAGNOSIS

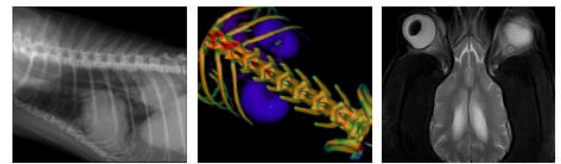
- Small lipoma in the right armpit.
- No evidence of pulmonary metastases.
- Splenic and hepatic nodules.
- Old right renal infarct – unlikely to be of clinical significance.
- Caudal pole nodule of the left adrenal gland.
- Spondyloses
- Degenerative lumbosacral stenosis.

INTERPRETATION OF THE FINDINGS & FURTHER RECOMMENDATIONS

A small lipoma is seen in the right armpit.

The hepatic and splenic nodules are likely to represent regenerative nodules, benign nodular hyperplasia and/or extramedullary hematopoiesis. Neoplasia including metastatic disease is thought unlikely even though this can never be ruled out entirely.

The nodule within the caudal pole of the left adrenal gland may represent a myelolipoma. Early adenoma, adenocarcinoma, nodular hyperplasia, early pheochromocytoma, or incidentaloma are possible differential diagnoses. Correlation with the laboratory values recommended.



PATIENT

Tiutia Dewitt

SPECIES

Canine

BREED

Caucasian Shepherd
Dog

SEX

FS

AGE

7 Years

INTERPRETED BY

Nele Eley, DVM
Dr. med. Vet. DipECVDI

HOSPITAL NAME

Catskill Veterinary
Services, PLLC

REFERRING VET

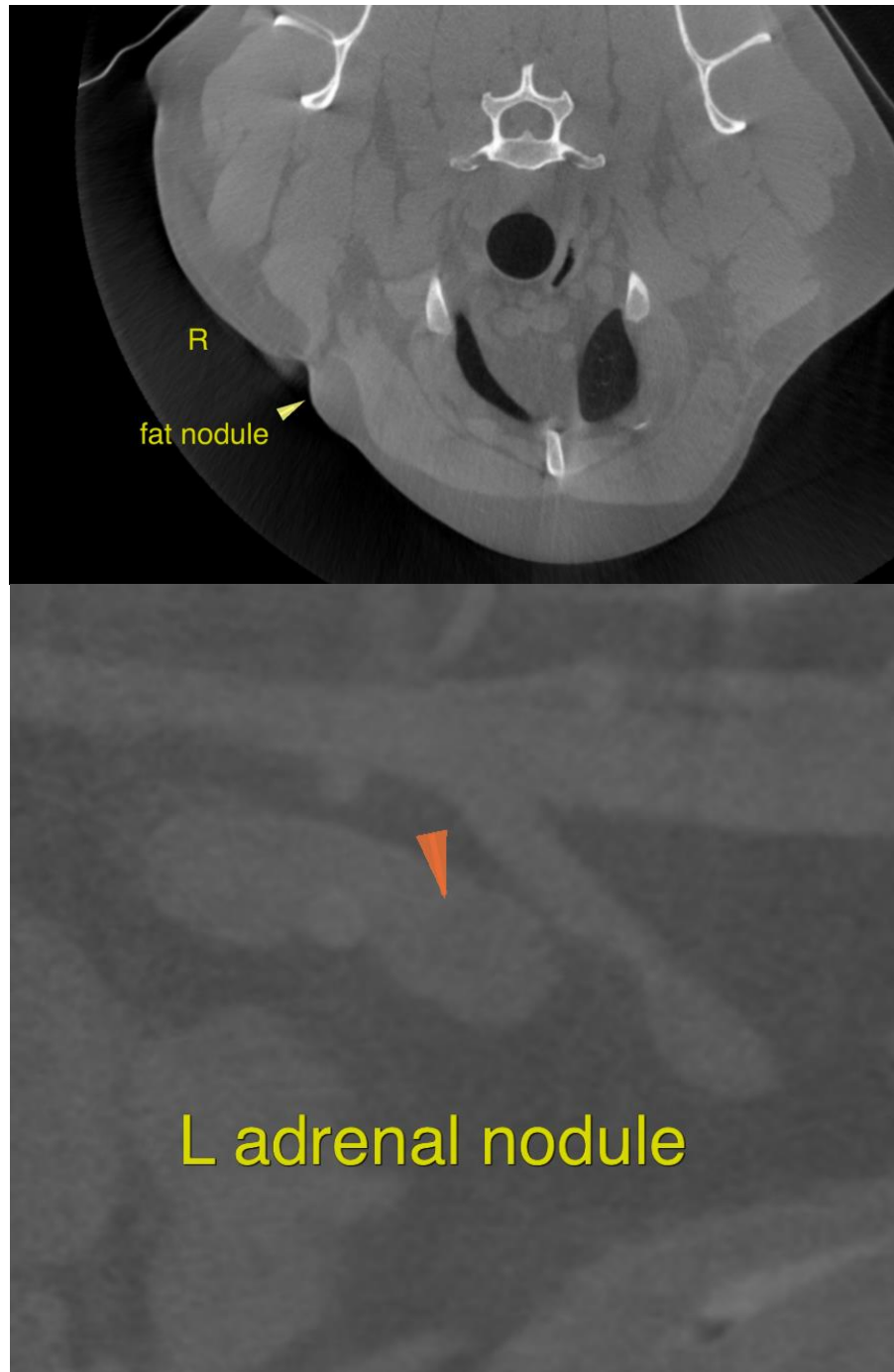
Dr. Daniela Carbone

INVOICE

55715

DATE

12-19-22





PATIENT

Tiutia Dewitt

The information and recommendations provided are based on the images presented by the referring veterinarian/sonographer. No evaluation can be communicated regarding pathology that was not visible in the image/video clips provided.

Thank you for this referral. If the clinical or image interpretation does not parallel your findings or if I can be of any further assistance please contact me.

SPECIES

Canine

Nele Eley, DVM, Dr. med. vet., DipECVDI
European Specialist in Veterinary Diagnostic Imaging, Cert. Radiology,
Senior lecturer University of Giessen, Germany, Veterinary Faculty, Department of Radiology
Nele.Eley@sonopath.com

BREED

Caucasian Shepherd
Dog

SEX

FS

AGE

7 Years

INTERPRETED BY

Nele Eley, DVM
Dr. med. Vet. DipECVDI

HOSPITAL NAME

Catskill Veterinary
Services, PLLC

REFERRING VET

Dr. Daniela Carbone

INVOICE

55715

DATE

12-19-22