



PATIENT

Lola Bialek

PRESENTING CLINICAL SIGNS

Gastroenteritis vs Foreign body

SPECIES

Rabbit

RADIOGRAPHIC STUDY OF THE ABDOMEN

Right/left lateral and ventrodorsal views of the abdomen totaling 4 images available for review.

BREED

Dwarf

RADIOGRAPHIC FINDINGS

There appears to be reduced serosal detail in the ventral abdomen and central abdominal mesentery.

SEX

Female

The stomach is dilated with a moderate amount of ingesta and a mild amount of gas. No fluid dilation of the stomach is seen.

There appears to be mild supranormal segmental dilation of the small intestine with fluid and gas content. Absence of the typical gas content within the cecum is noted.

The large intestine appears to be empty.

AGE

3 Years

RADIOGRAPHIC DIAGNOSIS

- Conflicting radiographic presentation for gastrointestinal ileus in combination with reduced serosal detail.

INTERPRETED BY

Nele Eley, DVM
Dr. med. Vet. DipECVDI

INTERPRETATION OF THE FINDINGS & FURTHER RECOMMENDATIONS

A combination of gastric dilation with fluid and gas and small intestinal dilation as well as absence of gas within the cecum has been described in rabbits as typical trios of radiographic signs of mechanical small intestinal obstruction. Absence of gas within the cecum and mild supranormal segmental dilation of the small intestine are seen here. There is however no evidence of radiopaque foreign material, and the fluid dilation of the stomach is lacking to render the radiographic findings pathognomonic for mechanical ileus. Moreover, presence of regional effusion within the ventral abdomen or peritonitis is suspected and further definition by means of full abdominal ultrasound is strongly recommended if not performed already in order to further verify the radiographic potential for small intestinal ileus and further define the nature of the presumed fluid accumulation.

HOSPITAL NAME

Truscott Animal
Hospital

REFERRING VET

Dr. Medhat Meawad

INVOICE

55716

DATE

12-19-22



PATIENT

Lola Bialek

SPECIES

Rabbit

BREED

Dwarf

SEX

Female

AGE

3 Years

INTERPRETED BY

Nele Eley, DVM
Dr. med. Vet. DipECVDI

HOSPITAL NAME

Truscott Animal
Hospital

REFERRING VET

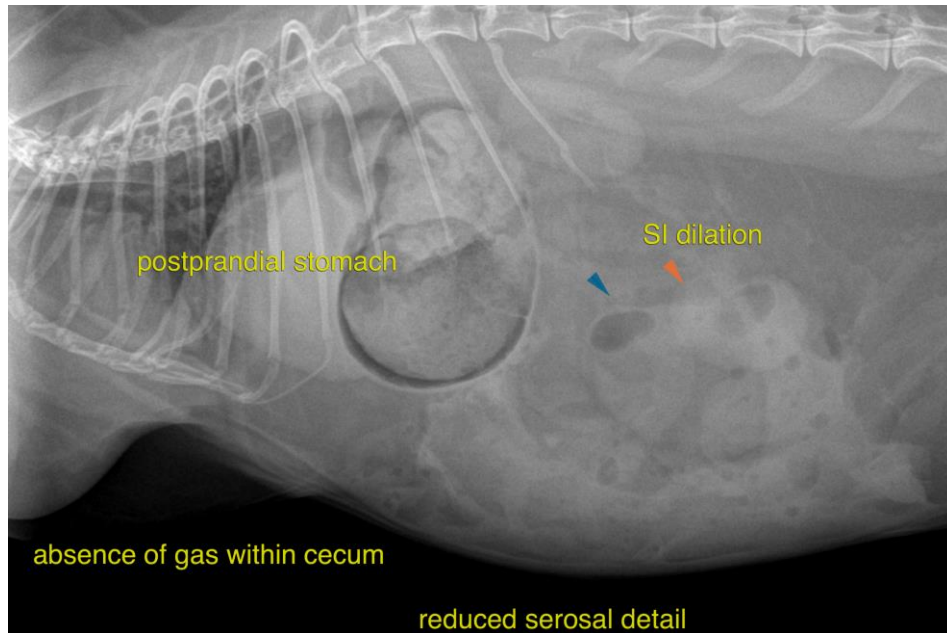
Dr. Medhat Meawad

INVOICE

55716

DATE

12-19-22



The information and recommendations provided are based on the images presented by the referring veterinarian/sonographer. No evaluation can be communicated regarding pathology that was not visible in the image/video clips provided.

Thank you for this referral. If the clinical or image interpretation does not parallel your findings or if I can be of any further assistance please contact me.

Nele Eley, DVM, Dr. med. vet., DipECVDI
European Specialist in Veterinary Diagnostic Imaging, Cert. Radiology,
Senior lecturer University of Giessen, Germany, Veterinary Faculty, Department of Radiology
Nele.Eley@sonopath.com