



PATIENT

Cricket Wilson-Bass

SPECIES

Feline

BREED

Domestic Shorthair

SEX

Female Spayed

AGE

2 Years

INTERPRETED BY

Nele Eley, DVM
Dr. med. Vet. DipECVDI

HOSPITAL NAME

St. Catherine's Animal
Hospital

REFERRING VET

Dr. Jui Gokhale

INVOICE

55710

DATE

12-19-22

PRESENTING CLINICAL SIGNS

inappetant for 10 days, vomiting once/day, not has had a BM in a week, urinating okay, lethargic, owner not sure about potential foreign body
Abnormal PE/Chem/CBC/UA Results: Icteric MM, temp WNL, moderately distended abdomen, ALP 336 (0-90), Bil 116 (0-9) ALT 171 (0-100)

RADIOGRAPHIC STUDY OF THE ABDOMEN

Right/left lateral and ventrodorsal views of the abdomen totaling 3 images available for review.

RADIOGRAPHIC FINDINGS

The abdominal serosal detail is maintained.

Mild gastric aerophagia is noted.

The small intestinal loops are of even diameter and nondilated. No evidence of plication or radiopaque foreign material is seen.

The urinary bladder is mildly distended and of uniform opacity.

The kidneys present within normal limits.

The liver presents within the expected radiographic limits.

RADIOGRAPHIC DIAGNOSIS

- Normal radiographic presentation of the abdomen with no evidence of mechanical ileus or foreign material.

INTERPRETATION OF THE FINDINGS & FURTHER RECOMMENDATIONS

The radiographic study reveals no evidence of radiopaque foreign material, and no signs of mechanical ileus are seen. Abdominal ultrasound could be considered to further assess for gastrointestinal tract, biliary disease, pancreatopathy, cholangiohepatitis, and other biliary system pathology as potential underlying causes of the patient's clinical signs.



PATIENT

Cricket Wilson-Bass

SPECIES

Feline

BREED

Domestic Shorthair

SEX

Female Spayed

AGE

2 Years

INTERPRETED BY

Nele Eley, DVM
Dr. med. Vet. DipECVDI

HOSPITAL NAME

St. Catherine's Animal
Hospital

REFERRING VET

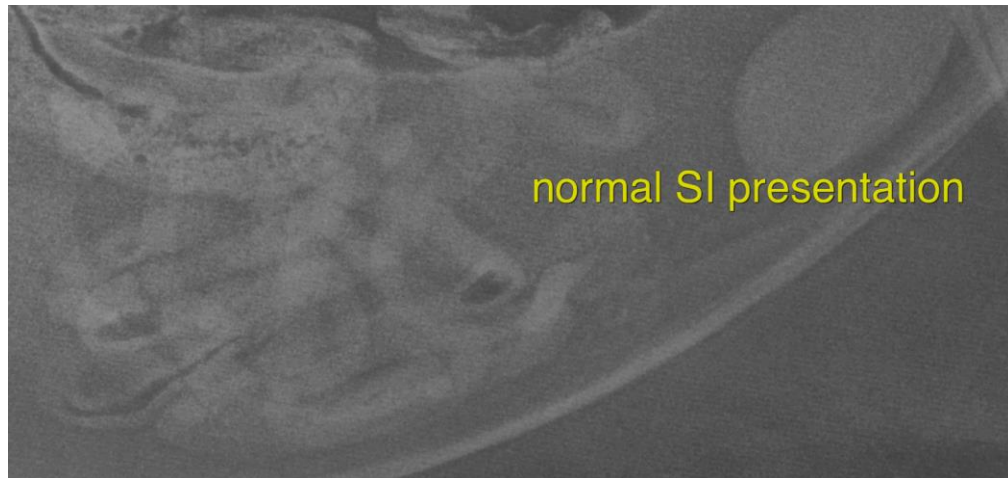
Dr. Jui Gokhale

INVOICE

55710

DATE

12-19-22



The information and recommendations provided are based on the images presented by the referring veterinarian/sonographer. No evaluation can be communicated regarding pathology that was not visible in the image/video clips provided.

Thank you for this referral. If the clinical or image interpretation does not parallel your findings or if I can be of any further assistance please contact me.

Nele Eley, DVM, Dr. med. vet., DipECVDI
European Specialist in Veterinary Diagnostic Imaging, Cert. Radiology,
Senior lecturer University of Giessen, Germany, Veterinary Faculty, Department of Radiology
Nele.Eley@sonopath.com