



**PATIENT PRESENTING CLINICAL SIGNS**

**Aston Davodi**  
 Repeat CT scan of the head (10-12-22). Previous CT submitted for signs of head tilt. Diagnosed with otitis media. Patient has responded well to treatment. Scan repeated to monitor treatment progress. Currently not clinical. Abdominal CT scan performed due to signs of urine leaking, patient has a urinary tract infection managed medically at this stage. Signs developed after a natural mating. CT for assessment of prostate and urinary tract. Abnormal PE/Chem/CBC/UA Results: N/A

**SPECIES**

Canine

**BREED**

French Bulldog

**COMPUTED TOMOGRAPHIC STUDY OF THE HEAD & ABDOMEN**

Plain and post contrast studies of the head and abdomen in soft tissue and bone windows available for review.

Compared to prior study dated 10-11-22.

**SEX**

ME

**COMPUTED TOMOGRAPHIC FINDINGS**

**Head**

Persistent chronic left sided otitis media with fluid attenuating contrast negative material filling the left tympanic bulla is seen. Smooth progressive thickening of the osseous lining of the left tympanic bulla is noted as well. There is no evidence of polyp formation or intracranial extension. The signs of left sided otitis externa are mildly regressive with a smaller amount of hypoattenuating material within the left external auditory meatus and milder thickening and enhancement of its epithelial lining.

The regional retropharyngeal and submandibular lymph nodes present within normal limits.

The dental findings are stationary compared with the prior study.

**AGE**

3.5 Years

**INTERPRETED BY**

Nele Eley, DVM  
 Dr. med. Vet. DipECVDI

**HOSPITAL NAME**

Colyton Veterinary Hospital

**Abdomen**

Moderate symmetric enlargement of the prostate measuring 3.5 x 3 x 2.5 cm is seen with small intraparenchymal cysts.

**REFERRING VET**

Dalton Nguyen

The urinary bladder is mildly distended. Mild generalized wall thickening of the urinary bladder is noted. The abdomen was scanned in an early post-contrast phase where pyelograms and ureteral enhancement are not seen yet, and presence of ureteral jets cannot be determined. However, no overt ureteral ectopia is noted.

The regional lymph nodes present within normal limits.

**INVOICE**

55704

The nephrogram of both kidneys presents within normal limits.

The liver, spleen, pancreas, and intestinal tract present within normal limits.

**DATE**

12-18-22

The adrenal glands present within normal limits.

A 4 cm sized elongated hyperattenuating structure is seen within the stomach. Food? Piece of rubber?



**PATIENT**

Aston Davodi

**SPECIES**

Canine

**BREED**

French Bulldog

**SEX**

ME

**AGE**

3.5 Years

**INTERPRETED BY**

Nele Eley, DVM  
Dr. med. Vet. DipECVDI

**HOSPITAL NAME**

Colyton Veterinary  
Hospital

**REFERRING VET**

Dalton Nguyen

**INVOICE**

55704

**DATE**

12-18-22

**COMPUTED TOMOGRAPHIC DIAGNOSIS**

- Persisting and mildly progressive chronic left sided otitis media.
- Mildly regressive otitis externa.
- Suspect chronic cystitis.
- Prostatomegaly of the entire male.
- No ureteral ectopia seen.

**INTERPRETATION OF THE FINDINGS & FURTHER RECOMMENDATIONS**

The smooth osseous new bone formation of the left tympanic bulla wall indicates mild progression of the otitis media. Evidence of intracranial extension is not seen at this point. The osteoproliferative changes appear to be well organized. The stenosis of the auditive tube may well contribute to the persistence or progression of the disease as in many brachycephalic dogs.

The otitis externa of the left external auditory meatus appears to be mildly regressive.

The findings of the urinary bladder support the presence of chronic cystitis/lower urinary tract infection. Ureteral ectopia is not seen even though the assessment does not allow full assessment of the exact position of the ureteral orifices.

The findings of the prostate are compatible with prostatic hyperplasia of the non-neutered male even though prostatitis and infiltrative disease can never be ruled out entirely.



**PATIENT**

Aston Davodi

**SPECIES**

Canine

**BREED**

French Bulldog

**SEX**

ME

**AGE**

3.5 Years

**INTERPRETED BY**

Nele Eley, DVM  
Dr. med. Vet. DipECVDI

**HOSPITAL NAME**

Colyton Veterinary  
Hospital

**REFERRING VET**

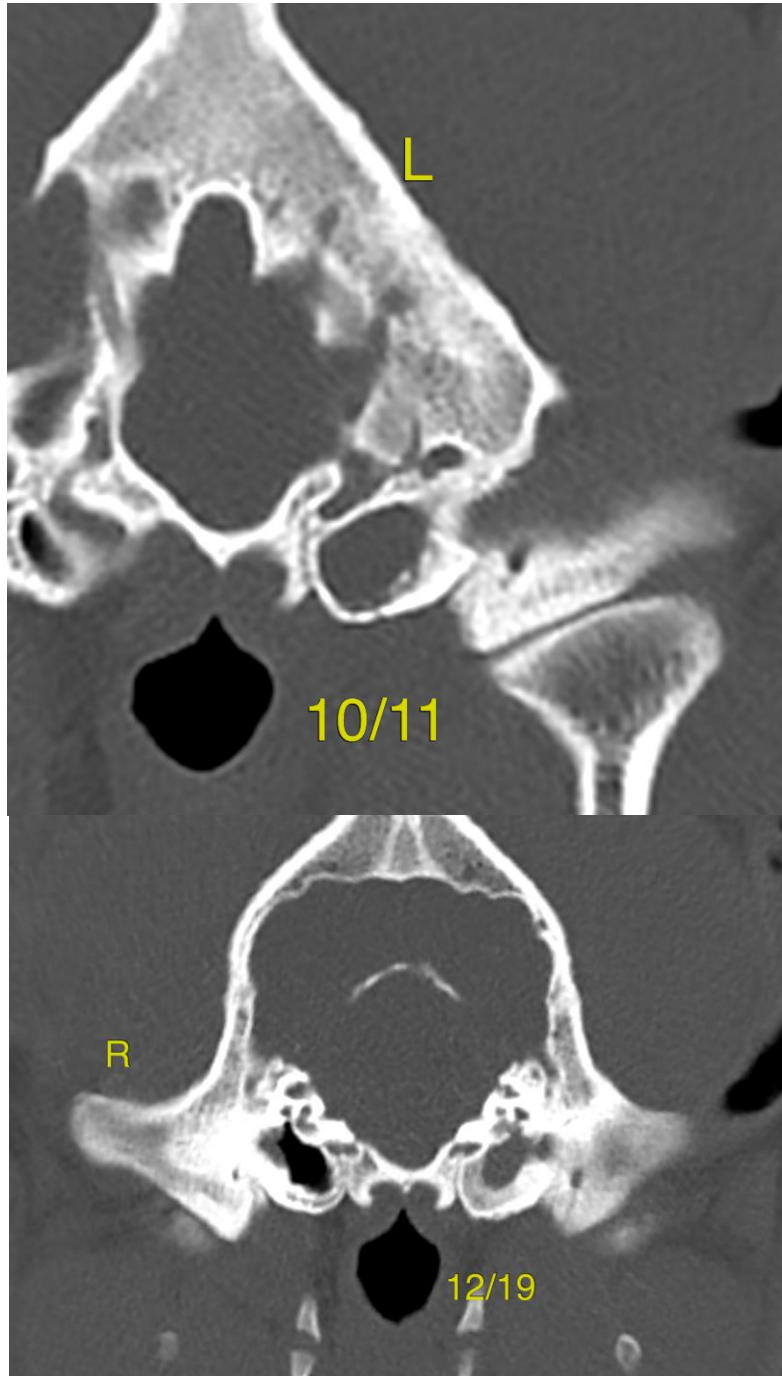
Dalton Nguyen

**INVOICE**

55704

**DATE**

12-18-22





**PATIENT**

Aston Davodi

**SPECIES**

Canine

**BREED**

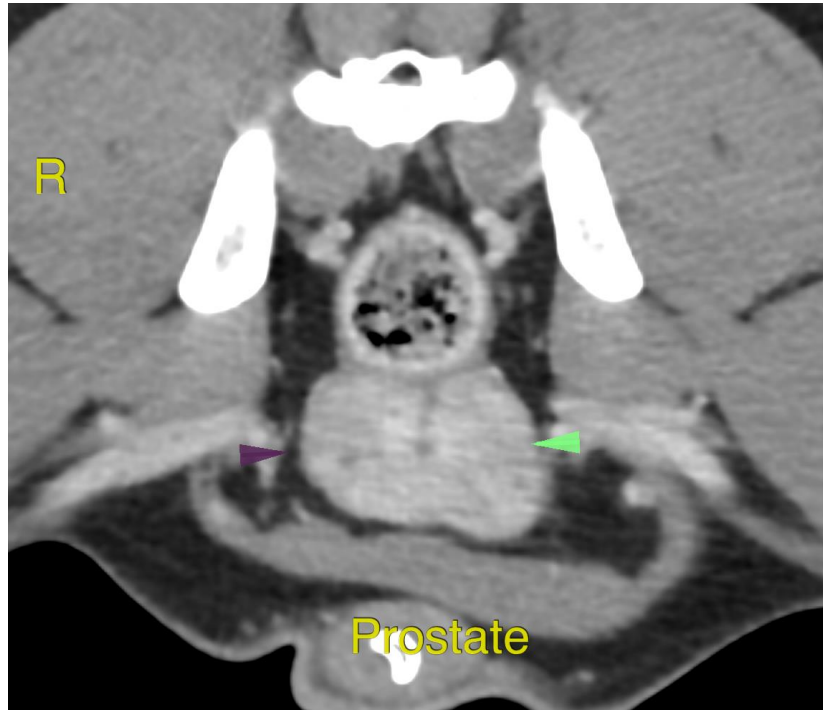French Bulldog

**SEX**

ME

**AGE**

3.5 Years



**INTERPRETED BY**

Nele Eley, DVM  
Dr. med. Vet. DipECVDI

The information and recommendations provided are based on the images presented by the referring veterinarian/sonographer. No evaluation can be communicated regarding pathology that was not visible in the image/video clips provided.

**HOSPITAL NAME**

Colyton Veterinary  
Hospital

Thank you for this referral. If the clinical or image interpretation does not parallel your findings or if I can be of any further assistance please contact me.

**Nele Eley**, DVM, Dr. med. vet., DipECVDI  
European Specialist in Veterinary Diagnostic Imaging, Cert. Radiology,  
Senior lecturer University of Giessen, Germany, Veterinary Faculty, Department of Radiology  
Nele.Eley@sonopath.com

**REFERRING VET**

Dalton Nguyen

**INVOICE**

55704

**DATE**

12-18-22