

**PATIENT**

Cooper Chandler

PRESENTING CLINICAL SIGNS

Hx. of pale mm, not eating coughing intermittently
Abnormal PE/Chem/CBC/UA Results: MM: pale pink , BW moderate neutrophilic leukocytosis , mild thrombocytopenia , mild decreased BUN

SPECIES

Canine

RADIOGRAPHIC STUDY OF THE THORAX

Left lateral and ventrodorsal views totaling 2 images available for review.

BREED

Dalmatian Mix

RADIOGRAPHIC FINDINGS

The lungs are deeply inflated. A generalized increase in pulmonary opacity based on a multinodular interstitial lung pattern is seen. The nodules vary in size between 1mm and 10mm. Moderate concurrent peribronchial cuffing is seen.

SEX

Male Neutered

There is no radiographic evidence of mediastinal lymphadenomegaly.

No pleural effusion is seen.

AGE

10 Years

The cardiovascular structures and trachea present within normal limits.

Mild gastric aerophagia is noted.

INTERPRETED BY

Nele Eley, DVM
Dr. med. Vet. DipECVDI

RADIOGRAPHIC DIAGNOSIS

- Nodular and miliary interstitial lung pattern.

INTERPRETATION OF THE FINDINGS & FURTHER RECOMMENDATIONS

The radiographic study reveals a multinodular interstitial lung pattern. Metastatic disease is a primary consideration and regarded the main differential diagnosis next to secondary neoplasia of the lung such as infiltration with round cell or pulmonary sarcoma and granulomatous pulmonary disease such as pulmonary infiltrates with eosinophils or fungal pneumonia.

Screening for a primary tumor could be considered as well as sampling either by means of ultrasound guided fine needle aspiration of peripherally situated interstitial nodules using an intercostal approach which typically has a good diagnostic yield and low procedure risk or airway endoscopy with lower airway sampling.

HOSPITAL NAME

St. Catherine's Animal
Hospital

REFERRING VET

Dr. Masoud

INVOICE

49133

DATE

12-18-21



PATIENT

Cooper Chandler

SPECIES

Canine

BREED

Dalmatian Mix

SEX

Male Neutered

AGE

10 Years

INTERPRETED BY

Nele Eley, DVM
Dr. med. Vet. DipECVDI

HOSPITAL NAME

St. Catherine's Animal
Hospital

REFERRING VET

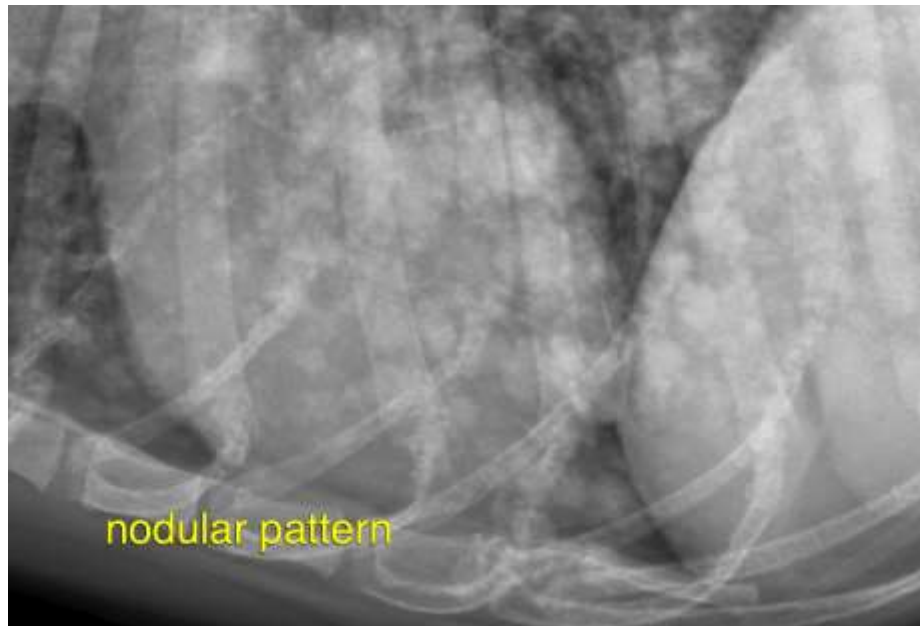
Dr. Masoud

INVOICE

49133

DATE

12-18-21



The information and recommendations provided are based on the images presented by the referring veterinarian. No evaluation can be communicated regarding pathology that was not visible in the image/video clips provided.

Thank you for this referral. If the clinical or image interpretation does not parallel your findings or if I can be of any further assistance please contact me.

Nele Eley, DVM, Dr. med. vet., DipECVDI
European Specialist in Veterinary Diagnostic Imaging, Cert. Radiology,
Senior lecturer University of Giessen, Germany, Veterinary Faculty, Department of Radiology
Nele.Eley@sonopath.com