



PATIENT

Cheese Hilton

SPECIES

Feline

BREED

Domestic Short Hair

SEX

MN

AGE

15

WEIGHT

3.7

INTERPRETED BY

Nele Eley (Ondreka),
DVM Dr. med. vet.,
DipECVDI

IMAGING PERFORMED BY

Alex R

HOSPITAL NAME

Pet Emergency & Referral
Center - NVA

REFERRING VET

Dr. Elizabeth Lechner-
Hines

INVOICE

73045

DATE

12-17-25

PRESENTING CLINICAL SIGNS

Pt diagnosed with bilateral fungal endophthalmitis (histoplasmosis) in 2020 - was managed on antifungals until about 2 months ago when patient started having stridor which has gotten progressively worse. Pt anesthetized for CT and biopsies to look for any sort of neoplasm stridor and nasal congestion but no discharge. No appreciable pathology on exam. Patient also has CKD. No current meds with the exception of fluconazole

COMPUTED TOMOGRAPHIC STUDY OF THE HEAD

Plain study available for review.

COMPUTED TOMOGRAPHIC FINDINGS

There appears to be hourglass shaped constrictive narrowing of the nasopharynx without surrounding mass effect. Nasal cavities, turbinates, and sinuses are symmetrical and unremarkable. No bone lysis or masses are seen.

Orbit and ocular structures are within normal limits.

The skull and cranial bones are intact with no evidence of lysis or abnormal periosteal reaction.

Normal morphology and attenuation of the brain parenchyma is seen.

The middle and inner ears present within normal limits.

The regional lymph nodes do not appear to be enlarged.

COMPUTED TOMOGRAPHIC DIAGNOSIS

- Suspect nasopharyngeal stenosis; otherwise normal CT study of the head.

INTERPRETATION OF FINDINGS & FURTHER RECOMMENDATIONS

The nasopharyngeal constriction suggests potential for nasopharyngeal stenosis which can be acquired secondary to chronic/recurring airway inflammation and less likely in this elderly patient, congenital. A positional artifact cannot be completely excluded but is considered less likely. Upper airway endoscopy is recommended to further verify for the presence of nasopharyngeal narrowing and dynamic obstruction.



PATIENT

Cheese Hilton

SPECIES

Feline

BREED

Domestic Short Hair

SEX

MN

AGE

15

WEIGHT

3.7

INTERPRETED BY

Nele Eley (Ondreka),
DVM Dr. med. vet.,
DipECVDI

IMAGING PERFORMED BY

Alex R

HOSPITAL NAME

Pet Emergency & Referral
Center - NVA

REFERRING VET

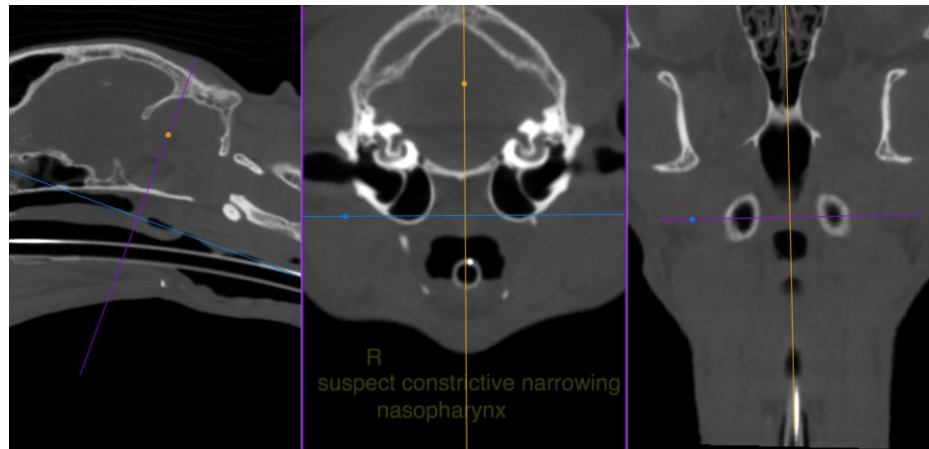
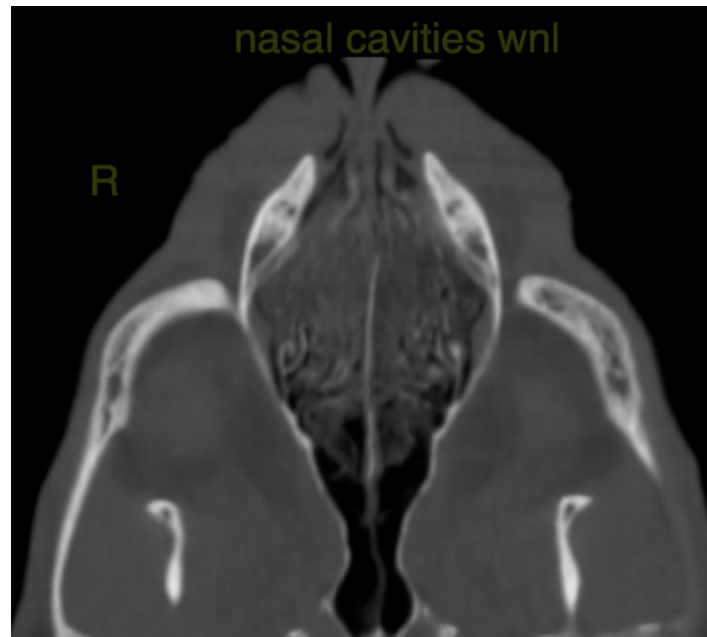
Dr. Elizabeth Lechner-
Hines

INVOICE

73045

DATE

12-17-25



The information and recommendations provided are based on the images presented by the referring veterinarian. No evaluation can be communicated regarding pathology that was not visible in the image/video clips provided.

Thank you for this referral. If the clinical or image interpretation does not parallel your findings or if I can be of any further assistance please contact me.

Nele Eley (Ondreka), DVM, Dr. med. vet., DipECVDI
European Specialist in Veterinary Diagnostic Imaging, Cert. Radiology,
Senior lecturer University of Giessen/Germany, Veterinary Faculty, Department of Radiology.
info@sonopath.com