



PATIENT

Sapphire Campbell

PRESENTING CLINICAL SIGNS

Reason for Visit: coughing History: Patient is presented today b/c O states that for the last 5 days P has started to sound congested especially while sleeping. O says that P sounds like she snoring while she breaths and is worried about a cold. P's nose has been dry or extra wet but no mucus like discharge. P is sneezing slightly & O thinks P hacked up a small amount of bial/flem. O also states P has not been her normal super friendly loving & inergetic self & P is always excited for food but last 2-3 days P has been a little slow to eat. Owner also mentions that they noticed the right side of P's neck seems a bit swollen & when husband was petting P there P growled at O like it hurt. P's rescue mate & new puppy are fine and acting normal. rescued about 1 yr ago & since adoption P has always had a small random cough that would happen every once and a while but over the last few days that coughing is now a few times a day every day, less playful and energetic recently. records in file. new puppy for 1 week, right side of neck swollen
 Abnormal PE/Chem/CBC/UA Results: Hydration: Adequate Mentation: QAR EENT: OU clear. AU clear, no debris. No cough on tracheal palpation. Oral cavity: moderate dental tartar. minimal gingivitis Lymph Nodes: left submandibular .ymph node is larger than the right, p seems sensitive to palpation, prescapular and popliteal lymph nodes normal size, shape and consistency Skin: Healthy hair coat. No ectoparasites seen, skin clean dry and intact. CV/Respiratory: Normal heart rate and rhythm, no murmur, pulses strong and synchronous, normal bronchovesicular sounds. Abd/GI: Soft, non-painful, no fluid wave, no palpable masses or organomegaly. Uro/Perineum: No lesions or abnormalities. Musculoskeletal: BCS = 7/9. obese Ambulatory x 4, sitfff gait, normal palpation all 4 limbs. Neurological: Alert and appropriate. No deficits noted.

SPECIES

Canine

BREED

Chihuahua

SEX

SF

AGE

5 Years

RADIOGRAPHIC STUDY OF THE THORAX

INTERPRETED BY

Nele Eley, DVM
 Dr. med. Vet. DipECVDI

Right lateral and ventrodorsal views of the thorax totaling 2 images available for review.

RADIOGRAPHIC FINDINGS

The patient is mildly obese.

HOSPITAL NAME

DPC Veterinary
 Hospital

The degree of pulmonary inflation is moderate. No significant alterations of the bronchopulmonary architecture are seen.

Course and width of the trachea are considered within normal limits. No bronchial collapse is noted.

REFERRING VET

Dr. Cepero

There is no evidence of abnormal mediastinal widening.

The pulmonary vasculature presents within normal limits. The cardiac silhouette presents within normal limits. No specific chamber enlargement is noted. The vertebral heart score is 8.5.

INVOICE

55686

There is moderate gastric aerophagia.

RADIOGRAPHIC DIAGNOSIS

- Normal radiographic presentation of the thoracic structures with no evidence of cardiovascular, tracheal, or bronchopulmonary pathology.
- Aerophagia.

DATE

12-17-22



PATIENT

Sapphire Campbell

SPECIES

Canine

BREED

Chihuahua

SEX

SF

AGE

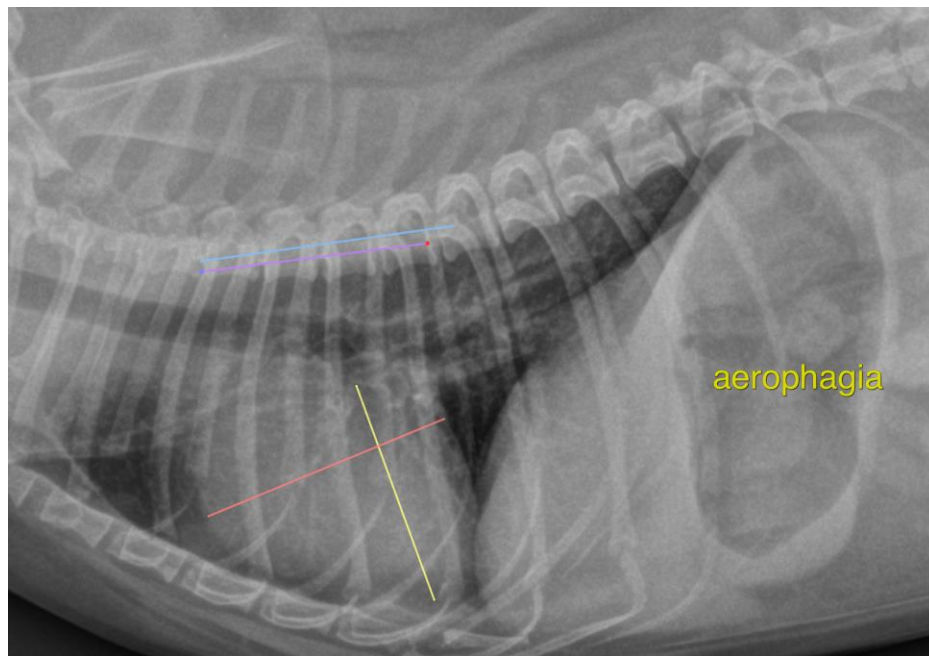
5 Years

INTERPRETED BY

Nele Eley, DVM
Dr. med. Vet. DipECVDI

INTERPRETATION OF THE FINDINGS & FURTHER RECOMMENDATIONS

The aerophagia is likely due to respiratory distress or general excitement. There is no evidence of bronchopulmonary pathology. The cardiovascular system presents within the expected radiographic limits. No evidence of dynamic tracheal or bronchial disease is noted. Consider the possibility of upper respiratory tract disease.



HOSPITAL NAME

DPC Veterinary
Hospital

REFERRING VET

Dr. Cepero

INVOICE

55686

DATE

12-17-22

The information and recommendations provided are based on the images presented by the referring veterinarian/sonographer. No evaluation can be communicated regarding pathology that was not visible in the image/video clips provided.

Thank you for this referral. If the clinical or image interpretation does not parallel your findings or if I can be of any further assistance please contact me.

Nele Eley, DVM, Dr. med. vet., DipECVDI
European Specialist in Veterinary Diagnostic Imaging, Cert. Radiology,
Senior lecturer University of Giessen, Germany, Veterinary Faculty, Department of Radiology
Nele.Eley@sonopath.com