


PATIENT PRESENTING CLINICAL SIGNS

Hope Portolano The vomiting started on Saturday. They caught her eating the fake Christmas tree and they blocked off the tree. Then the vomiting got worse. She would drink some water and turn around and vomit the water back up. They would feed her and she would keep that down for a few hours then throw that up.

SPECIES Hasnt really had an appetite this week. Has not use the litter box a whole lot either.

Feline Abnormal PE/Chem/CBC/UA Results: PE: RESPONSE TO DEEP PALATION OF ABDOMEN and STAGE I DENTAL No resent labs

RADIOGRAPHIC STUDY OF THE ABDOMEN
BREED

The surrounding bony structures are within normal limits.

DLH

No abnormalities of the extra-abdominal soft tissues are noted. The abdominal wall is smooth and thin.

SEX

The serosal detail is maintained throughout the peritoneal and retroperitoneal space.

Spayed Female

The liver is appropriate in position and size and presents uniform opacity.

AGE

The splenic head is in the anticipated position and within normal limits for size and opacity. The splenic tail is not seen.

10 Years 5 Months

Both kidneys are seen and present with normal size, shape, delineation, and opacity. The urinary bladder is in its anticipated position. No radiopaque calculi are noted throughout the upper and lower urinary tract.

INTERPRETED BY

Nele Eley (Ondreka),
 DVM Dr. med. vet.,
 DipECVDI

The stomach appears to be empty. No radiopaque foreign material is seen within the stomach. The small intestinal loops are evenly distributed throughout the mid abdomen. There is no evidence of abnormal dilation, plication, or radiopaque foreign material. The ascending and transverse colon contain a moderate amount of fecal matter. The fecal matter in the descending colon appears very inspissated.

HOSPITAL NAME

Elizabeth AH

RADIOGRAPHIC DIAGNOSIS

- No radiographic evidence of mechanical ileus or radiopaque foreign material
- Constipation and dehydration

REFERRING VET

Dr. Leon Anderson

INTERPRETATION OF FINDINGS & FURTHER RECOMMENDATIONS

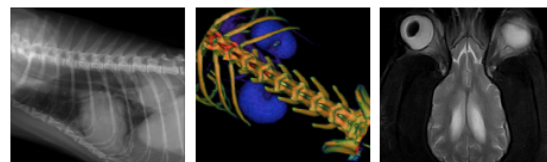
The radiographic study reveals no evidence of mechanical ileus or radiopaque foreign material. The patient appears dehydrated, and a moderate amount of inspissated fecal matter is seen within the colon.

INVOICE

33544

DATE

12/17/21



PATIENT

Hope Portolano

The information and recommendations provided are based on the images presented by the referring veterinarian. No evaluation can be communicated regarding pathology that was not visible in the image/video clips provided.

SPECIES

Feline

Thank you for this referral. If the clinical or image interpretation does not parallel your findings or if I can be of any further assistance please contact me.

BREED

DLH

Nele Eley (Ondreka), DVM, Dr. med. vet., DipECVDI
European Specialist in Veterinary Diagnostic Imaging, Cert. Radiology,
Senior lecturer University of Giessen/Germany, Veterinary Faculty, Department of Radiology.
Nele.Eley@sonopath.com

SEX

Spayed Female

AGE

10 Years 5 Months

INTERPRETED BY

Nele Eley (Ondreka),
DVM Dr. med. vet.,
DipECVDI

HOSPITAL NAME

Elizabeth AH

REFERRING VET

Dr. Leon Anderson

INVOICE

33544

DATE

12/17/21