



**PATIENT PRESENTING CLINICAL SIGNS**

Eldrick Basak RECHECK X RAYS ( original x rays 12/15/21)

**RADIOGRAPHIC STUDY OF THE ABDOMEN**

**SPECIES**

Compared to previous radiographs dated 12/15/21.

Canine

**RADIOGRAPHIC FINDINGS**

**BREED**

Lab

The new image set reveals 7 stones within the gastrointestinal tract, all of which appear to be situated within the colon, 6 of which are located in the transverse colon and 1 of which is in the most oral portion of the descending colon. No remaining foreign material is seen within the stomach or small intestine. No evidence of mechanical ileus is noted.

**SEX**

Male

**RADIOGRAPHIC DIAGNOSIS**

- Passage of gastrointestinal foreign material (stones) into the large intestine without radiographic evidence of complication.

**AGE**

6 Months

**INTERPRETATION OF FINDINGS & FURTHER RECOMMENDATIONS**

All stones appear to have passed the stomach and small intestine without causing mechanical ileus. The remaining stones are situated within the large intestine and should pass the natural way.

**INTERPRETED BY**

Nele Eley (Ondreka),  
DVM Dr. med. vet.,  
DipECVDI

**HOSPITAL NAME**

Long Valley AH

**REFERRING VET**

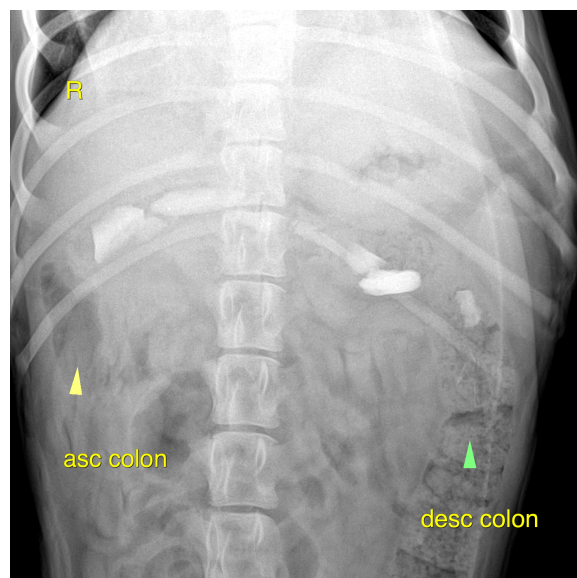
Dr. Lentis

**INVOICE**

33542

**DATE**

12/17/21





**PATIENT**

Eldrick Basak

The information and recommendations provided are based on the images presented by the referring veterinarian. No evaluation can be communicated regarding pathology that was not visible in the image/video clips provided.

**SPECIES**

Canine

Thank you for this referral. If the clinical or image interpretation does not parallel your findings or if I can be of any further assistance please contact me.

**BREED**

Lab

**Nele Eley (Ondreka)**, DVM, Dr. med. vet., DipECVDI  
European Specialist in Veterinary Diagnostic Imaging, Cert. Radiology,  
Senior lecturer University of Giessen/Germany, Veterinary Faculty, Department of Radiology.  
Nele.Eley@sonopath.com

**SEX**

Male

**AGE**

6 Months

**INTERPRETED BY**

Nele Eley (Ondreka),  
DVM Dr. med. vet.,  
DipECVDI

**HOSPITAL NAME**

Long Valley AH

**REFERRING VET**

Dr. Lentis

**INVOICE**

33542

**DATE**

12/17/21