



**PATIENT PRESENTING CLINICAL SIGNS**

Chloe Tufford Sudden onset of bloody vomiting and diarrhea  
Abnormal PE/Chem/CBC/UA Results: Unremarkable

**SPECIES RADIOGRAPHIC STUDY OF THE ABDOMEN**

Canine Right/left lateral and ventrodorsal views totaling 3 images available for review.

**RADIOGRAPHIC FINDINGS**

**BREED** The patient is in thin body condition. Mild generalized osteopenia is noted.

Shih Tzu The abdominal serosal detail appeared to be maintained.

**SEX** There is mild bilateral coxofemoral joint osteoarthritis secondary to canine hip dysplasia.

Spayed Female Mild generalized dilation of the small intestinal loops is seen. The stomach and colon appear to be empty.

**AGE** The kidneys, liver and urinary bladder present no deviation from their expected radiographic anatomy.

14 Years The splenic head is within normal limits.

**RADIOGRAPHIC DIAGNOSIS**

**INTERPRETED BY**

Nele Eley (Ondreka),  
DVM Dr. med. vet.,  
DipECVDI

- Functional small intestinal ileus
- Presumably age related osteopenia
- Moderate bilateral coxofemoral osteoarthritis

**INTERPRETATION OF FINDINGS & FURTHER RECOMMENDATIONS**

**HOSPITAL NAME**

St. Catharine's AH

The radiographic findings suggest the presence of paralytic/functional small intestinal ileus, which may be associated with gastroenteritis, pancreatopathy, electrolyte imbalances or other. Correlate with laboratory values and consider abdominal ultrasound for further definition depending on the severity, duration and development of the patient's clinical signs. There is no radiographic evidence of mechanical obstruction.

**REFERRING VET**

Dr. Masoud

**INVOICE**

33552

**DATE**

12/17/21



**PATIENT**

Chloe Tufford

**SPECIES**

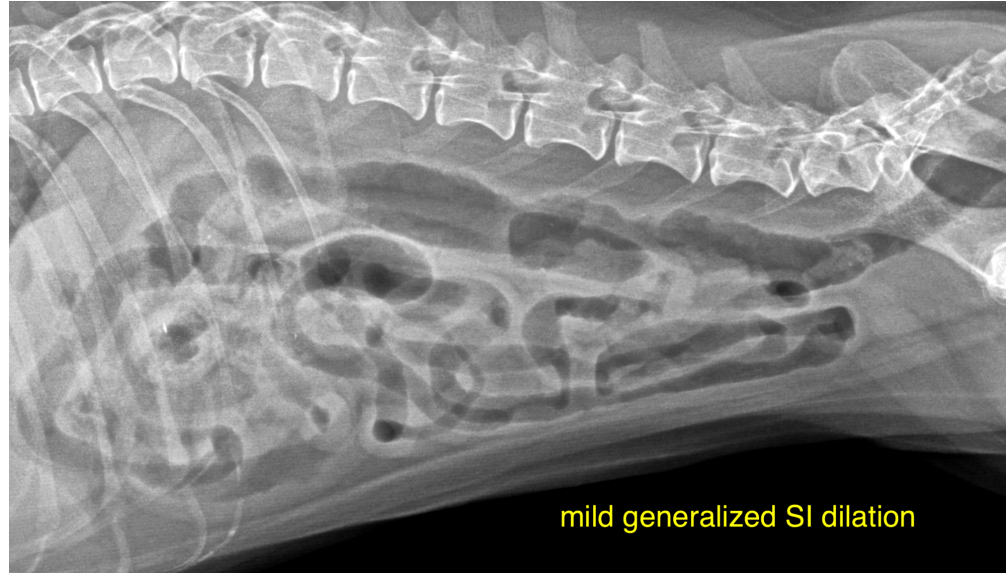
Canine

**BREED**

Shih Tzu

**SEX**

Spayed Female



**AGE**

14 Years

The information and recommendations provided are based on the images presented by the referring veterinarian. No evaluation can be communicated regarding pathology that was not visible in the image/video clips provided.

Thank you for this referral. If the clinical or image interpretation does not parallel your findings or if I can be of any further assistance please contact me.

**INTERPRETED BY**

Nele Eley (Ondreka),  
DVM Dr. med. vet.,  
DipECVDI

**Nele Eley (Ondreka)**, DVM, Dr. med. vet., DipECVDI  
European Specialist in Veterinary Diagnostic Imaging, Cert. Radiology,  
Senior lecturer University of Giessen/Germany, Veterinary Faculty, Department of Radiology.  
Nele.Eley@sonopath.com

**HOSPITAL NAME**

St. Catharine's AH

**REFERRING VET**

Dr. Masoud

**INVOICE**

33552

**DATE**

12/17/21