



**PATIENT**

Jakar Maiden

**PRESENTING CLINICAL SIGNS**

Has a bad back. He hasn't been getting up. Won't take treats. His breathing is hard and it looks like he is breathing from his abdomen. His head has been down. Listless. U/D normal. No vomiting.

**SPECIES**

Abnormal PE/Chem/CBC/UA Results: Lethargic. Tachycardic. Tachypnic with respiratory effort.

Canine

**RADIOGRAPHIC STUDY OF THE THORAX & ABDOMEN**

**BREED**

Right/left lateral and ventrodorsal views of the thorax and lateral views of the abdomen totaling 7 images available for review.

Maremma Sheepdog

**RADIOGRAPHIC FINDINGS**

**SEX**

**Thorax**

MN

The surrounding bony structures are within normal limits.

The extrathoracic soft tissues present homogeneous without abnormalities.

**AGE**

The cardiac silhouette presents upright and thin. The caudal vena cava and pulmonary vasculature are thin. The vertebral heart score is 8.5.

6 Years, 6 Months

The cranial mediastinum presents the expected soft tissue opacity. The mediastinal width is less than twice the width of the vertebral column at the same level.

**INTERPRETED BY**

Nele Eley, DVM  
Dr. med. Vet. DipECVDI

The trachea is normal in diameter and presents the anticipated course. The luminal outline of the trachea is smooth.

**HOSPITAL NAME**

Elizabeth Animal  
Hospital

The bronchial tree presents with thin walls and tapers uniformly towards the periphery as expected.

The lung parenchyma presents the expected architecture and opacity. The intrapulmonary vascular branching is seen up to the third order lung vessels.

**REFERRING VET**

Leon Anderson, DVM

The diaphragm is well delineated with even surface and the expected mild cranial bulging of the diaphragmatic cupola.

**Abdomen**

**INVOICE**

The abdominal serosal detail is reduced in the center of the abdomen with granulated appearance of the serosal fat in the periphery.

55685

Turgid appearance of the small intestine with crowding of small intestine in the ventral mid abdomen is noted. A discrepant gas pattern with segmental gas accumulations and clusters of gas bubbles are seen with no overt dilation or plication of the small intestinal loops.

**DATE**

12-16-22



**PATIENT**

Jakar Maiden

**RADIOGRAPHIC DIAGNOSIS**

- Reduced serosal detail with suspect enteropathy.
- Hypovolemia with microcardia and underperfusion of the lung.

**SPECIES**

Canine

**INTERPRETATION OF THE FINDINGS & FURTHER RECOMMENDATIONS**

The reduced serosal detail in the abdomen may be due to presence of free peritoneal fluid or regional peritonitis. Concurrent enteropathy or mesenteropathy with no direct signs of mechanical ileus is suggested by the radiographic findings of the small intestine. Further definition by means of full abdominal ultrasound is strongly recommended if not performed already.

**BREED**

Maremma Sheepdog

**SEX**

MN

**AGE**

6 Years, 6 Months

**INTERPRETED BY**

Nele Eley, DVM  
Dr. med. Vet. DipECVDI

**HOSPITAL NAME**

Elizabeth Animal  
Hospital

**REFERRING VET**

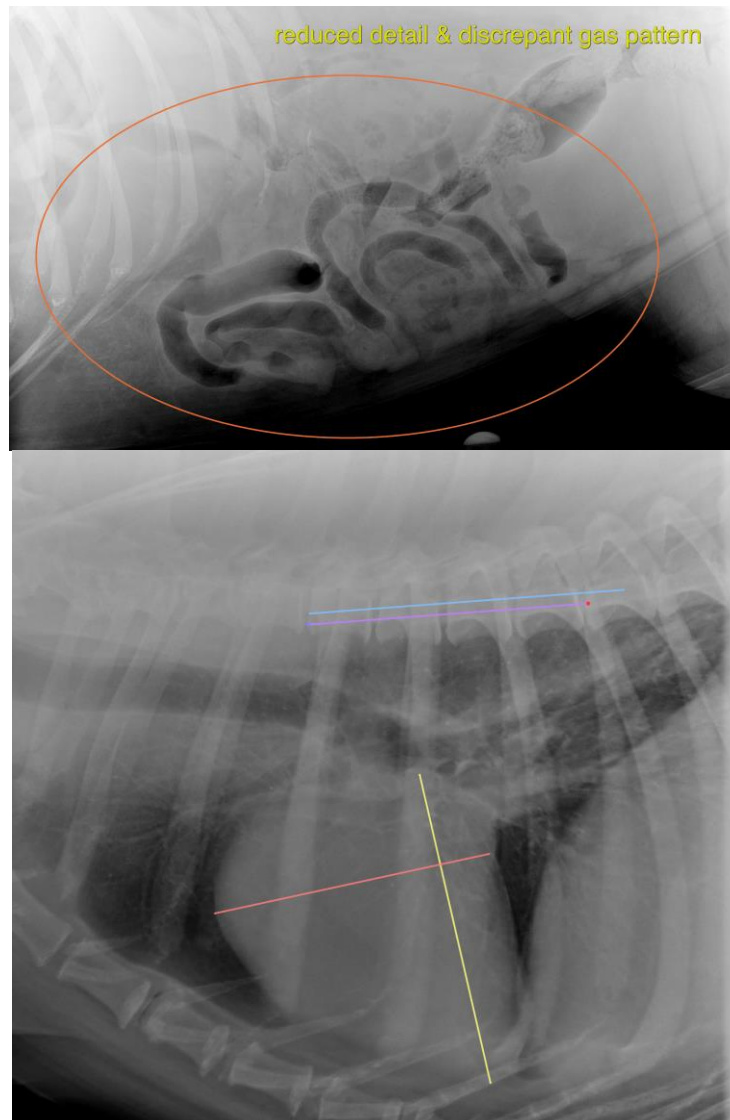
Leon Anderson, DVM

**INVOICE**

55685

**DATE**

12-16-22





**PATIENT**

Jakar Maiden

The information and recommendations provided are based on the images presented by the referring veterinarian/sonographer. No evaluation can be communicated regarding pathology that was not visible in the image/video clips provided.

**SPECIES**

Canine

Thank you for this referral. If the clinical or image interpretation does not parallel your findings or if I can be of any further assistance please contact me.

**BREED**

Maremma Sheepdog

**Nele Eley**, DVM, Dr. med. vet., DipECVDI  
European Specialist in Veterinary Diagnostic Imaging, Cert. Radiology,  
Senior lecturer University of Giessen, Germany, Veterinary Faculty, Department of Radiology  
Nele.Eley@sonopath.com

**SEX**

MN

**AGE**

6 Years, 6 Months

**INTERPRETED BY**

Nele Eley, DVM  
Dr. med. Vet. DipECVDI

**HOSPITAL NAME**

Elizabeth Animal  
Hospital

**REFERRING VET**

Leon Anderson, DVM

**INVOICE**

55685

**DATE**

12-16-22