



## PATIENT

Linden Reed

## SPECIES

Canine

## BREED

Karelian Bear Dog

## SEX

MN

## AGE

4Y

## WEIGHT

34kg

## INTERPRETED BY

Nele Eley (Ondreka),  
DVM Dr. med. vet.,  
DipECVCI

## IMAGING PERFORMED BY

David Lane

## HOSPITAL NAME

Points East West  
Veterinary Services

## REFERRING VET

David Lane

## INVOICE

72998

## DATE

12-15-25

## PRESENTING CLINICAL SIGNS

Chronic wax/wane LFL lameness flared by exercise. Diagnosed as supraspinatus tendinopathy via CT and U/S at another facility. Corticosteroids were injected "in and around the insertion of the supraspinatus muscle" yielding a 4 week partial response. Elbow OA without effusion was found on CT. On examination, no pain could be localized to the elbow or on shoulder manipulation. Moderate point tenderness was palpable in the caudolateral aspect of the left shoulder joint, along the distal margin of the infraspinatus tendon, and over the region of the teres minor tendon, but I could not localize the pathoanatomic location beyond that.

## ULTRASONOGRAPHIC FINDINGS

### Left Shoulder

The supraspinatus tendon is moderately remodeled with heterogeneous echotexture, hypoechoic areas, and occasional hyperechoic foci are noted. The average maximum thickness measures 8.5mm. Mild early enthesiophyte formation is present at the greater humeral tubercle. There is secondary impingement of the biceps tendon but no significant effusion or tenosynovitis is observed at this point, and the biceps tendon fibers remain structurally intact.

The infraspinatus and teres minor tendons appear normal with regular fiber pattern and echogenicity.

The left subscapularis tendon is within normal limits.

Part of the left caudal humerus is visible and demonstrates osseous remodeling with mild new bone formation.

### Right Shoulder

The supraspinatus tendon is moderately remodeled with heterogeneous echotexture, hypoechoic areas, and occasional hyperechoic foci are noted. The average maximum thickness measures 8.5mm. Mild early enthesiophyte formation is present at the greater humeral tubercle. There is secondary impingement of the biceps tendon but no significant effusion or tenosynovitis is observed at this point, and the biceps tendon fibers remain structurally intact.

The infraspinatus and teres minor tendons appear normal with regular fiber pattern and echogenicity.

The right subscapularis tendon is within normal limits.

## ULTRASONOGRAPHIC DIAGNOSIS

- Bilateral supraspinatus tendinopathy with secondary biceps impingement without structural or inflammatory changes.
- Normal ultrasonographic presentation of the bilateral infraspinatus, teres minor, and subscapularis tendons.
- Focal remodeling of the left caudal humerus periarticular margin.

## INTERPRETATION OF FINDINGS & FURTHER RECOMMENDATIONS

The bilateral supraspinatus tendon demonstrates moderate signs of tendinopathy with early enthesiophyte formation at the greater humeral tubercles. The findings are consistent with chronic bilateral supraspinatus tendinopathy which may correlate with the forelimb lameness, however, the changes are bilateral and symmetric.



## PATIENT

Linden Reed

## SPECIES

Canine

## BREED

Karelian Bear Dog

## SEX

MN

## AGE

4Y

## WEIGHT

34kg

## INTERPRETED BY

Nele Eley (Ondreka),  
DVM Dr. med. vet.,  
DipECVDI

## IMAGING PERFORMED BY

David Lane

## HOSPITAL NAME

Points East West  
Veterinary Services

## REFERRING VET

David Lane

## INVOICE

72998

## DATE

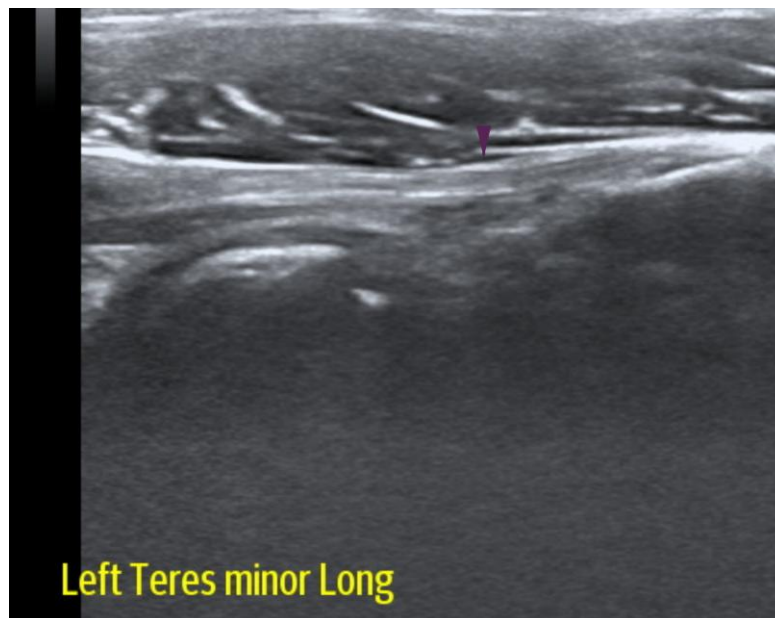
12-15-25

Secondary biceps impingement is noted. However, the absence of tenosynovitis or fiber disruption suggests that the biceps tendon is not currently the primary source of pain.

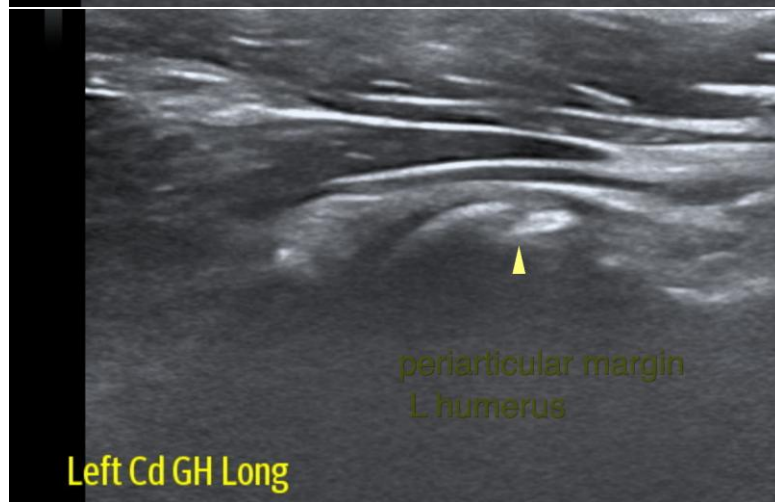
The other shoulder tendons including infraspinatus, teres minor, and subscapularis appear normal.

The remodeling and new bone formation observed in the left caudal humerus may contribute to the discomfort during palpation.

A definitive source of lameness aside from the bilateral supraspinatus changes and osseous changes of the periarticular margin of the left caudal humerus cannot be identified. Correlation with the corresponding radiographs and orthopedic consultation are recommended.



Left Teres minor Long



periarticular margin  
L. humerus

Left Cd GH Long



## PATIENT

Linden Reed

## SPECIES

Canine

## BREED

Karelian Bear Dog

## SEX

MN

## AGE

4Y

## WEIGHT

34kg

## INTERPRETED BY

Nele Eley (Ondreka),  
DVM Dr. med. vet.,  
DipECVDI

## IMAGING PERFORMED BY

David Lane

## HOSPITAL NAME

Points East West  
Veterinary Services

## REFERRING VET

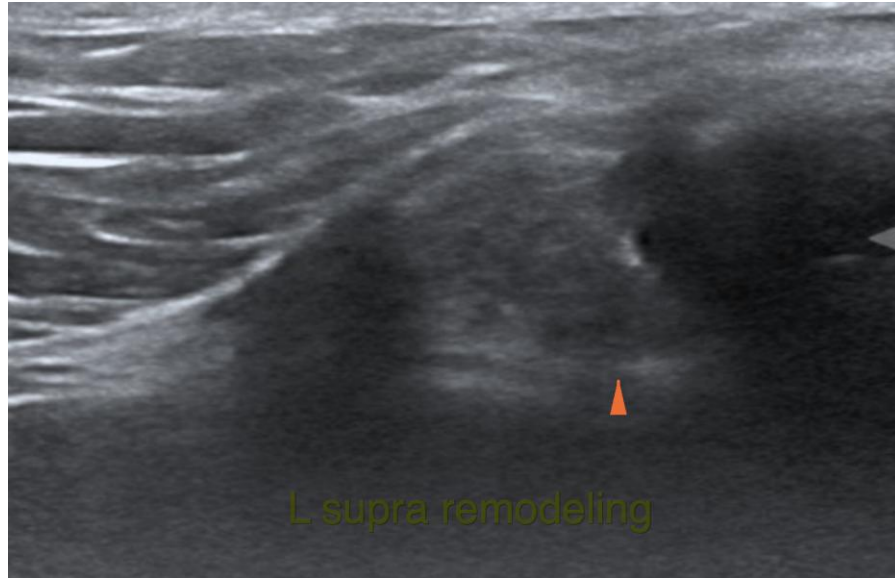
David Lane

## INVOICE

72998

## DATE

12-15-25



The information and recommendations provided are based on the images presented by the referring veterinarian. No evaluation can be communicated regarding pathology that was not visible in the image/video clips provided.

Thank you for this referral. If the clinical or image interpretation does not parallel your findings or if I can be of any further assistance please contact me.

**Nele Eley (Ondreka)**, DVM, Dr. med. vet., DipECVDI  
European Specialist in Veterinary Diagnostic Imaging, Cert. Radiology,  
Senior lecturer University of Giessen/Germany, Veterinary Faculty, Department of Radiology.  
[info@sonopath.com](mailto:info@sonopath.com)