



PATIENT

Hugo Givnan

SPECIES

Canine

BREED

Staffordshire Bull
Terrier

SEX

Male

AGE

3Y

WEIGHT

28kg

INTERPRETED BY

Nele Eley (Ondreka),
DVM Dr. med. vet.,
DipECVDI

IMAGING PERFORMED BY

Michelle Pacaud RVN

HOSPITAL NAME

Animal Trust - Ellesmere
Port

REFERRING VET

Noah's Ark Veterinary
Centre

INVOICE

72983

DATE

12-15-25

PRESENTING CLINICAL SIGNS

Limping started again start december Lump on L HL between 4th and 5 th digit foot appeared previously in June and October aswell as limb swelling Lump was fluid filled and caused limping Limping and lump resolved with antibiotics and anti-inflammatories but recurred Wound:L HL paw between 4th and 5 th digit mass fluid filled, visible on top and bottom of the foot pad, pink and inflamed. CE otherwise nad Dx: Foreign body suspected; interdigital cyst and tumour considered as differential diagnoses Suggested DFFX: Interdigital cyst, tumour

COMPUTED TOMOGRAPHIC STUDY OF THE LEFT FRONT PAW

History says hind paw but imaged is the left front paw.

The carpometacarpal and phalangeal bones of the left front paw are normally aligned. The axial sesamoid bone of the left 5th metacarpophalangeal joint appears multipartite with moderate degenerative changes. Mild focal soft tissue swelling is present between the 4th and 5th digits of the left front paw involving both dorsal and palmar aspects. There is no discrete foreign body appreciated. Superficial focal dirt artifacts are noted between the pads but do not appear to be intralesional. No additional soft tissue masses are identified. There is no evidence of osteolytic or osteoproliferative changes.

COMPUTED TOMOGRAPHIC DIAGNOSIS

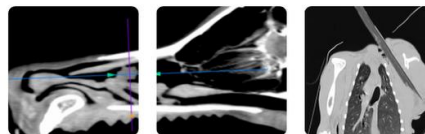
- Mild focal soft tissue swelling dorsal and palmar between the 4th and 5th digit of the left front paw.
- No foreign body identified.
- Multipartite axial sesamoid bone of the metacarpophalangeal joint of the 5th digit with moderate osteoarthritis.

INTERPRETATION OF FINDINGS & FURTHER RECOMMENDATIONS

The CT study does not reveal a discrete foreign body or neoplastic mass as the cause of the recurrent interdigital swelling. Non attenuating foreign material cannot be ruled out entirely, however, interdigital cyst and other dermatopathy are possible differential diagnoses.

The multipartite sesamoid bone and associated osteoarthritic changes of the 5th metacarpophalangeal joint may contribute to the lameness or discomfort but do not explain the recurrent swelling.

Clinical correlation is recommended including consideration of biopsy of the soft tissue swelling.



PATIENT

Hugo Givnan

SPECIES

Canine

BREED

Staffordshire Bull
Terrier

SEX

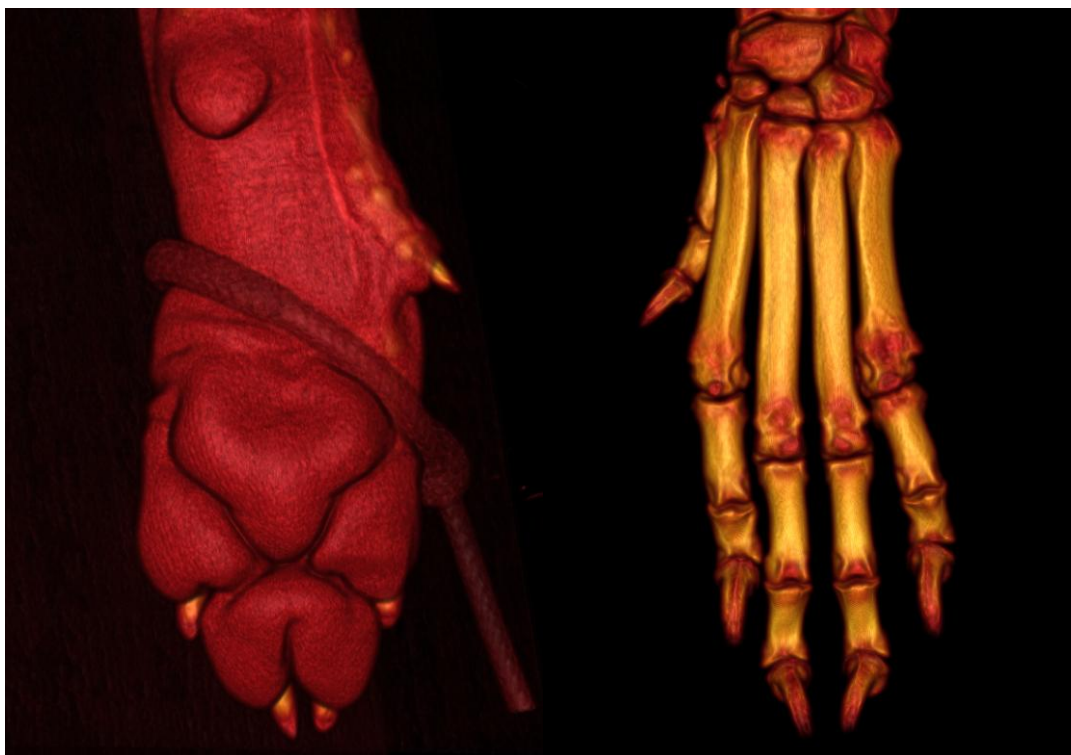Male

AGE

3Y

WEIGHT

28kg



INTERPRETED BY

Nele Eley (Ondreka),
DVM Dr. med. vet.,
DipECVDI

IMAGING PERFORMED BY

Michelle Pacaud RVN

HOSPITAL NAME

Animal Trust - Ellesmere
Port

REFERRING VET

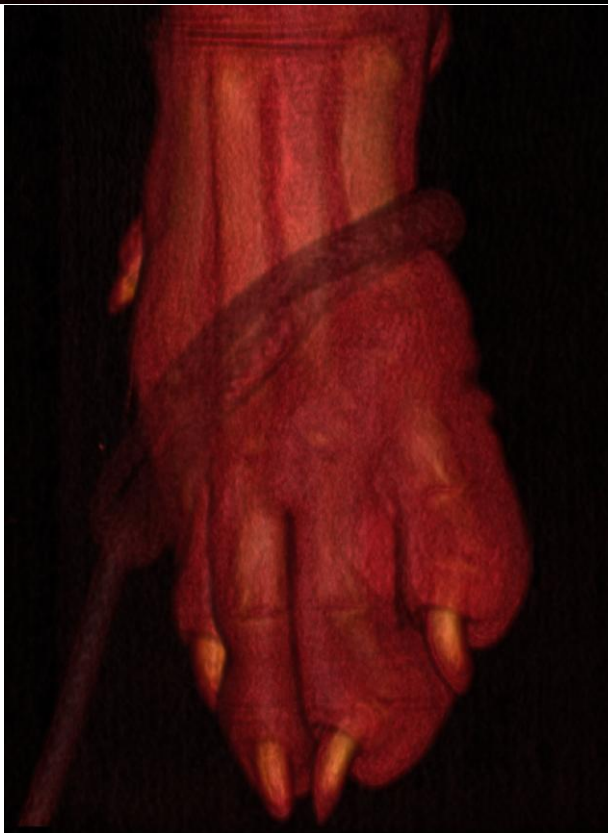Noah's Ark Veterinary
Centre

INVOICE

72983

DATE

12-15-25





PATIENT

Hugo Givnan

SPECIES

Canine

BREED

Staffordshire Bull
Terrier

SEX

Male

AGE

3Y

WEIGHT

28kg

INTERPRETED BY

Nele Eley (Ondreka),
DVM Dr. med. vet.,
DipECVDI

IMAGING PERFORMED BY

Michelle Pacaud RVN

HOSPITAL NAME

Animal Trust - Ellesmere
Port

REFERRING VET

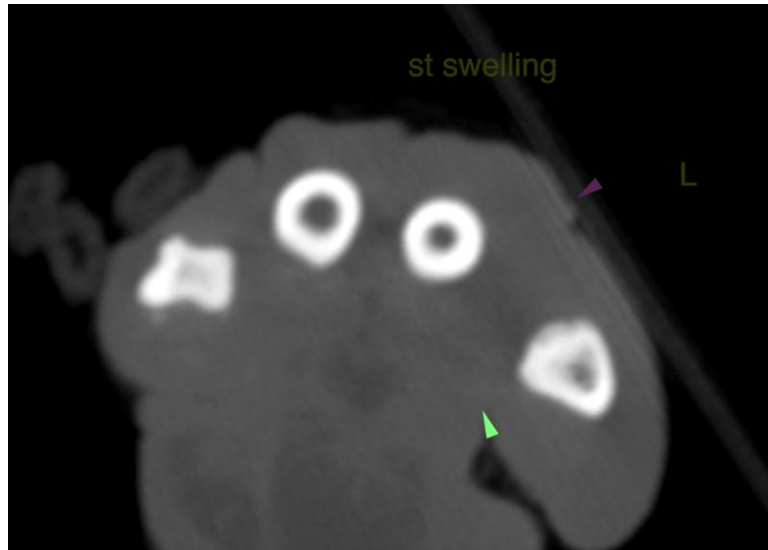
Noah's Ark Veterinary
Centre

INVOICE

72983

DATE

12-15-25



The information and recommendations provided are based on the images presented by the referring veterinarian. No evaluation can be communicated regarding pathology that was not visible in the image/video clips provided.

Thank you for this referral. If the clinical or image interpretation does not parallel your findings or if I can be of any further assistance please contact me.

Nele Eley (Ondreka), DVM, Dr. med. vet., DipECVDI
European Specialist in Veterinary Diagnostic Imaging, Cert. Radiology,
Senior lecturer University of Giessen/Germany, Veterinary Faculty, Department of Radiology.
info@sonopath.com