



PATIENT PRESENTING CLINICAL SIGNS

Lucy Barber
 Lucy presented with a swelling to the right hind limb that has been variably present for approximately 1-1.5 years. With minimal lameness or pain. Primary DVM noted a mass on the medial aspect of the limb a few months ago. Conservative medical management was attempted at that time and the patient was treated with antibiotics and NSAIDs with little to no change. Primary DVM noted some growth on recent recheck and recommended surgical evaluation.
SPECIES
 Canine
 Abnormal PE/Chem/CBC/UA Results: Mild neutrophilia and monocytosis, mild hyperglycemia, and mild increases in globulins and alk phos.

BREED COMPUTED TOMOGRAPHIC STUDY OF THE RIGHT HIND LIMB

Shepherd Mix
 Plain and post contrast studies available for review.

COMPUTED TOMOGRAPHIC FINDINGS

SEX
 Female Spay
 Medial patella luxation of the right stifle joint is seen. The right stifle joint presents mild osteoarthritic changes.

AGE
 ~10 Years
 Extensive multifocal muscular soft tissue swelling with mass effect is seen in the right hind limb involving the area around the popliteal vessels as well as the semitendinosus, semimembranosus, abductor, gracilis, and sartorius muscles, which present disrupted muscular architecture with decreased attenuation and decreased enhancement as well as ill-defined margins and mass effect. There also is cavitation and a severe mass effect of the tibialis cranialis muscle distal and lateral of the right stifle.

INTERPRETED BY

Nele Eley, DVM
 Dr. med. Vet. DipECVDI
 Mild symmetric enlargement of the popliteal lymph nodes is seen as well as extensive subcutaneous fat stranding accentuating the medial and caudal aspect level with and distal of the knee.

HOSPITAL NAME

COMPUTED TOMOGRAPHIC DIAGNOSIS

Bluegrass Veterinary
 Specialists

- Multiple myopathy with disrupted muscular architecture and mass effect in the right hind limb.
- Medial patella luxation and mild osteoarthritis of the right knee.
- Mild popliteal lymphadenomegaly.

REFERRING VET

INTERPRETATION OF THE FINDINGS & FURTHER RECOMMENDATIONS

Guevara

The CT findings are compatible with multifocal hematoma and muscle rupture in the right hind limb. Multiple muscle involvement proximal and distal of the knee is identified. The subcutaneous fluid may represent edema or hemorrhage. A discreet enhancing mass is not seen; however, the mass effect, especially in the popliteal region, is severe and neoplasia with hemorrhage cannot be ruled out entirely as a differential diagnosis. Tissue sampling is strongly recommended for further definition.

INVOICE

49060

The medial patella luxation of the right stifle joint may not be associated with the multiple muscular pathology in the right hind limb; however, developmental, and traumatic medial patella luxation are both a potential.

DATE

12-15-21



PATIENT

Lucy Barber

SPECIES

Canine

BREED

Shepherd Mix

SEX

Female Spay

AGE

~10 Years

INTERPRETED BY

Nele Eley, DVM
Dr. med. Vet. DipECVDI

HOSPITAL NAME

Bluegrass Veterinary
Specialists

REFERRING VET

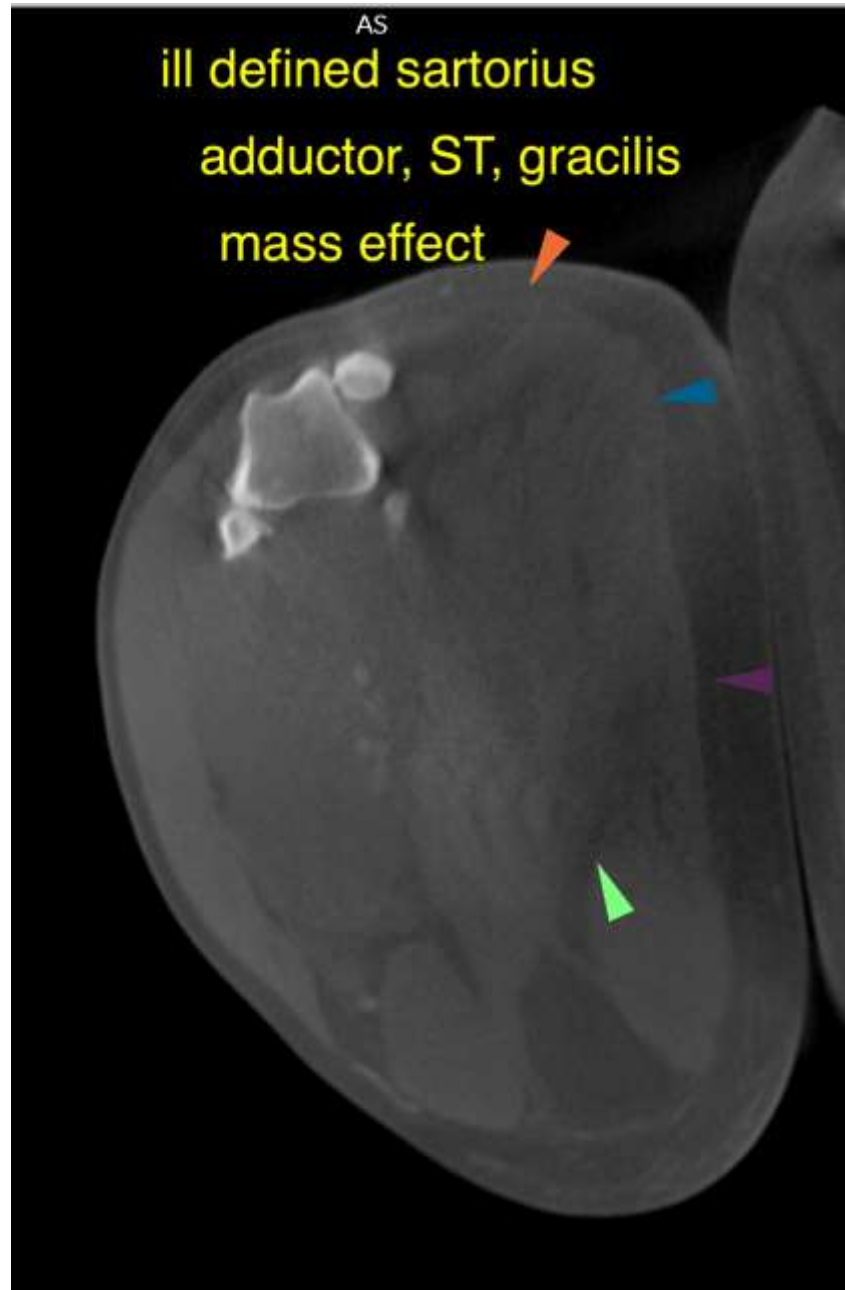
Guevara

INVOICE

49060

DATE

12-15-21





PATIENT

Lucy Barber

SPECIES

Canine

BREED

Shepherd Mix

SEX

Female Spay

AGE

~10 Years

INTERPRETED BY

Nele Eley, DVM
Dr. med. Vet. DipECVDI

HOSPITAL NAME

Bluegrass Veterinary
Specialists

REFERRING VET

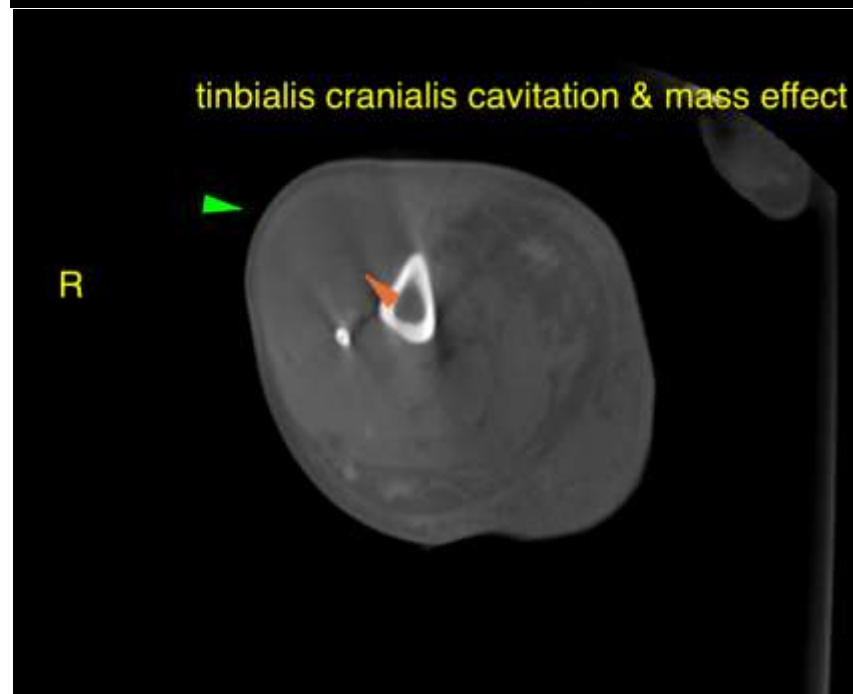
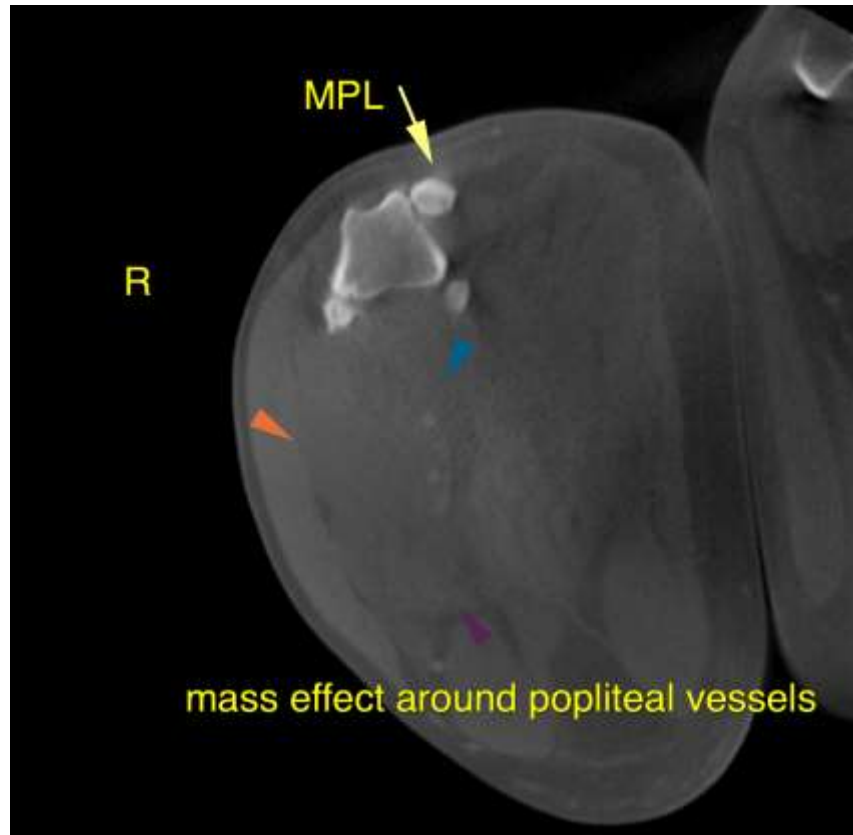
Guevara

INVOICE

49060

DATE

12-15-21





PATIENT

Lucy Barber

The information and recommendations provided are based on the images presented by the referring veterinarian. No evaluation can be communicated regarding pathology that was not visible in the image/video clips provided.

SPECIES

Canine

Thank you for this referral. If the clinical or image interpretation does not parallel your findings or if I can be of any further assistance please contact me.

BREED

Shepherd Mix

Nele Eley, DVM, Dr. med. vet., DipECVDI
European Specialist in Veterinary Diagnostic Imaging, Cert. Radiology,
Senior lecturer University of Giessen, Germany, Veterinary Faculty, Department of Radiology
Nele.Eley@sonopath.com

SEX

Female Spay

AGE

~10 Years

INTERPRETED BY

Nele Eley, DVM
Dr. med. Vet. DipECVDI

HOSPITAL NAME

Bluegrass Veterinary
Specialists

REFERRING VET

Guevara

INVOICE

49060

DATE

12-15-21