



**PATIENT**

Kiki Cajigas

**PRESENTING CLINICAL SIGNS**

Pt presented for not eating for the last couple of days to a week. Pt not drinking much, not much in the litterbox. O reports pt defecates every 3 days or so. Pt acting normal, no lethargy. BW/UA/FPL pending.

**SPECIES**

Feline

**RADIOGRAPHIC STUDY OF THE ABDOMEN**

Right lateral and ventrodorsal views of the abdomen totaling 3 images available for review.

**BREED**

DSH

**RADIOGRAPHIC FINDINGS**

The surrounding bony structures are within normal limits.

**SEX**

SF

No abnormalities of the extraabdominal soft tissues are noted. The abdominal wall is smooth and thin.

The serosal detail is maintained throughout the peritoneal and retroperitoneal space.

The liver is appropriate in position, size and presents uniform opacity.

**AGE**

4.5 Years

The splenic head is in the anticipated position and within normal limits for size and opacity. The splenic tail is not seen.

**INTERPRETED BY**

Nele Eley, DVM  
Dr. med. Vet. DipECVDI

Both kidneys are seen and present with normal size, shape, delineation and opacity. The urinary bladder is in its anticipated position. No radiopaque calculi are noted throughout the upper and lower urinary tract.

The stomach is empty.

**HOSPITAL NAME**

The Pet Hospital of  
Stratford

The small intestinal loops contain a moderate amount of gas. No significant dilation of the small intestine is noted. The small intestinal loops are somewhat turgid in appearance.

The large intestine contains a mild amount of fecal matter. No evidence of constipation is noted.

**RADIOGRAPHIC DIAGNOSIS**

**REFERRING VET**

Dr. Giuliani

- Small intestinal maldigestion pattern with no evidence of mechanical ileus.

**INTERPRETATION OF THE FINDINGS & FURTHER RECOMMENDATIONS**

The radiographic study reveals no signs of mechanical / obstructive ileus. Functional ileus is a likely potential based on the radiographic findings. Further definition by means of abdominal ultrasound could be considered in case of persisting or deteriorating clinical signs.

**INVOICE**

55594

**DATE**

12-14-22



**PATIENT**

Kiki Cajigas

**SPECIES**

Feline

**BREED**

DSH

**SEX**

SF

**AGE**

4.5 Years

**INTERPRETED BY**

Nele Eley, DVM  
Dr. med. Vet. DipECVDI

**HOSPITAL NAME**

The Pet Hospital of  
Stratford

**REFERRING VET**

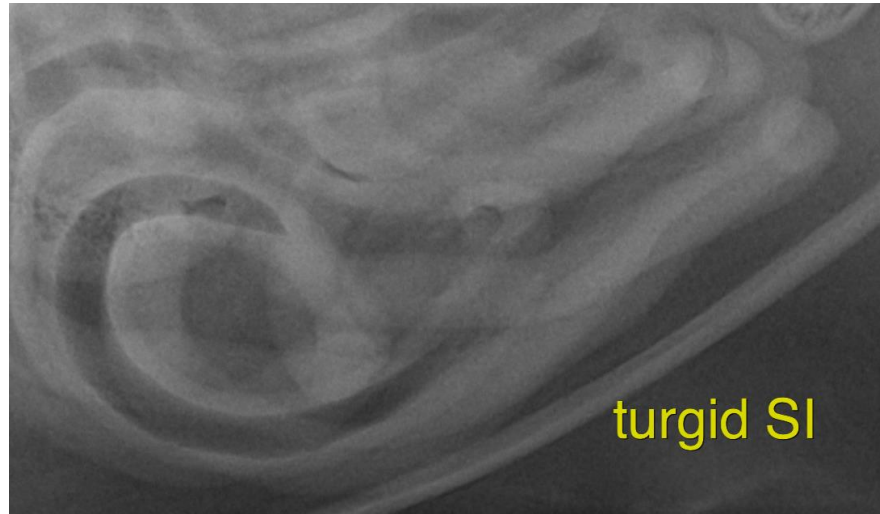
Dr. Giuliani

**INVOICE**

55594

**DATE**

12-14-22



The information and recommendations provided are based on the images presented by the referring veterinarian/sonographer. No evaluation can be communicated regarding pathology that was not visible in the image/video clips provided.

Thank you for this referral. If the clinical or image interpretation does not parallel your findings or if I can be of any further assistance please contact me.

**Nele Eley**, DVM, Dr. med. vet., DipECVDI  
European Specialist in Veterinary Diagnostic Imaging, Cert. Radiology,  
Senior lecturer University of Giessen, Germany, Veterinary Faculty, Department of Radiology  
Nele.Eley@sonopath.com