



PATIENT

Sherlock Ray

SPECIES

Canine

BREED

Lab X

SEX

MN

AGE

7Y

WEIGHT

66.8kg

INTERPRETED BY

Nele Eley (Ondreka),
DVM Dr. med. vet.,
DipECVDI

IMAGING PERFORMED BY

Alexa Jones

HOSPITAL NAME

Alberta Veterinary
Dentistry

REFERRING VET

Dr. Kriti Saxena

INVOICE

72961

DATE

12-11-25

PRESENTING CLINICAL SIGNS

Since Oct 21 2025, Hx of left sided nasal discharge. Slowly has progressed to now blood-tinged snot dripping and being sneezed out. The severity and frequency of the sneezing has increased drastically over the last two weeks. Previous nasal flush and maropitant nasal drops trial with no improvement and due to difficulty administering, this was discontinued at the beginning of Nov. No other medical intervention for the nose over the last two months from O account and rDVM records. When the referral to our service was sent a week ago, there was a 4x3cm soft tissue mass over medial OS. It has significantly grown from what was described in size (~12x9cm).

Abnormal PE/Chem/CBC/UA Results: EPOC results WNL for today. ~12x9cm soft tissue mass over OS extending medially and cranially over the bridge of the nose.

COMPUTED TOMOGRAPHIC STUDY OF THE HEAD

Plain study available for review only.

COMPUTED TOMOGRAPHIC FINDINGS

A large, left sided, irregularly shaped, and ill-defined nasal cavity mass measuring approximately 9 x 7 x 4 cm is seen. The mass occupies the left nasal cavity and extends medially across the nasal septum as well as onto the dorsum of the nose. There is lysis of the cribriform plate with extension into the cranial vault. Left orbital involvement is noted as well. The mass is soft tissue attenuating. Marked destruction of the left nasal turbinates, nasal septum, and permeative lysis of the nasal, maxillary, and frontal bones, left bony orbit, and cribriform plate is seen.

COMPUTED TOMOGRAPHIC DIAGNOSIS

- Large left nasal soft tissue mass with paranasal and intracranial extension meeting neoplastic criteria.

INTERPRETATION OF FINDINGS & FURTHER RECOMMENDATIONS

The CT study reveals a large mass with aggressive biological behavior emerging from the left nasal cavity with paranasal extension including the bridge of the nose and the cranial vault. Most likely differentials include nasal adenocarcinoma, squamous cell carcinoma, transitional cell carcinoma, and less likely lymphoma, or sarcoma. The mass demonstrates all hallmarks of high grade malignant intranasal tumor. Complete surgical excision is not feasible. Intracranial extension also limits external beam radiation; however, radiation remains the treatment of choice for carcinoma if palliation or partial tumor control is desired. Biopsy and histology are recommended for a definitive diagnosis. FNA of the regional lymph nodes and thoracic imaging can be considered for complete staging as well.



PATIENT

Sherlock Ray

SPECIES

Canine

BREED

Lab X

SEX

MN

AGE

7Y

WEIGHT

66.8kg

INTERPRETED BY

Nele Eley (Ondreka),
DVM Dr. med. vet.,
DipECVDI

IMAGING PERFORMED BY

Alexa Jones

HOSPITAL NAME

Alberta Veterinary
Dentistry

REFERRING VET

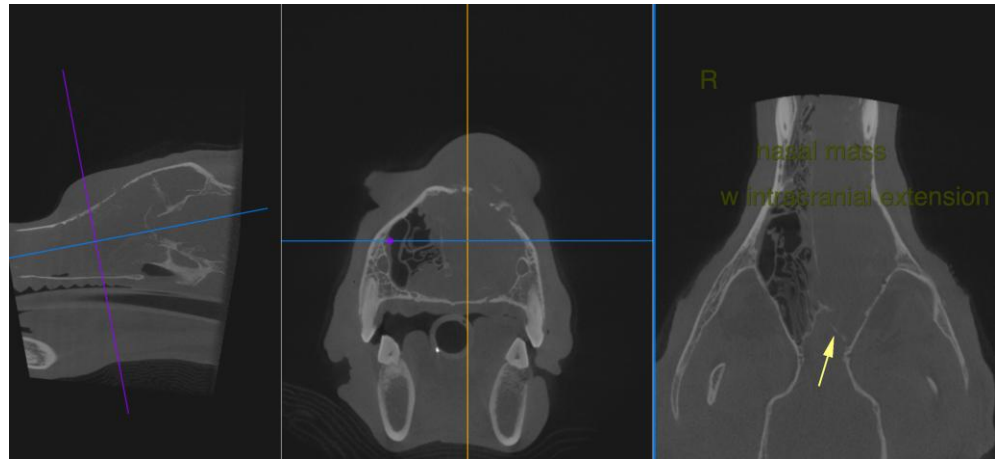
Dr. Kriti Saxena

INVOICE

72961

DATE

12-11-25



The information and recommendations provided are based on the images presented by the referring veterinarian. No evaluation can be communicated regarding pathology that was not visible in the image/video clips provided.

Thank you for this referral. If the clinical or image interpretation does not parallel your findings or if I can be of any further assistance please contact me.

Nele Eley (Ondreka), DVM, Dr. med. vet., DipECVDI
European Specialist in Veterinary Diagnostic Imaging, Cert. Radiology,
Senior lecturer University of Giessen/Germany, Veterinary Faculty, Department of Radiology.
info@sonopath.com