



PATIENT

Coco Abou

SPECIES

K9

BREED

Bernese Mtn Dog

SEX

FS

AGE

8Y, 10M

WEIGHT

41kg

INTERPRETED BY

Nele Eley (Ondreka),
DVM Dr. med. vet.,
DipECVDI

IMAGING PERFORMED BY

Mobile Pet Imaging

HOSPITAL NAME

Mobile Pet Imaging

REFERRING VET

Armstrong

INVOICE

72799

DATE

12-1-25

PRESENTING CLINICAL SIGNS

Presenting complaint or concern (brief) Mass on the external right ear.

Abnormal PE/Chem/CBC/UA Results: Pe- pigmented mass on the R external ear canal. Smaller than a golf ball. Pic of mass will be sent via email.

COMPUTED TOMOGRAPHIC STUDY OF THE HEAD

Plain and post contrast studies are available for review.

COMPUTED TOMOGRAPHIC FINDINGS

A cauliflower shaped pedunculated mass measuring approximately 17 x 16 x 15mm is located at the craniodorsal margin of the right ear canal at the base of the pinna. Heterogeneous contrast enhancement is noted within the soft tissue attenuating mass.

The regional submandibular and retropharyngeal lymph nodes are unremarkable.

Ectopic dental tissue of enamel density measuring approximately 20mm is seen in the rostral aspect of the left frontal sinus and inert.

A uniformly fat attenuating, smoothly delineated, left retropharyngeal mass measuring approximately 35mm is seen.

COMPUTED TOMOGRAPHIC DIAGNOSIS

- Right external ear canal pedunculated soft tissue mass
- Left retropharyngeal lipoma
- Ectopic dental tissue in the left frontal sinus.
- Normal regional lymph nodes.

INTERPRETATION OF FINDINGS & FURTHER RECOMMENDATIONS

The right ear canal mass is pedunculated with heterogeneous enhancement and cauliflower like morphology suggestive of ear canal soft tissue neoplasia such as ceruminous gland adenoma/adenocarcinoma, squamous cell carcinoma, melanoma, or other. Biopsy and histology are required for a definitive diagnosis.

The regional lymph nodes present within normal limits suggesting no current evidence of metastasis.

Surgical or oncologic evaluation of the right ear canal mass with excisional biopsy or TECA can be considered.



PATIENT

Coco Abou

SPECIES

K9

BREED

Bernese Mtn Dog

SEX

FS

AGE

8Y, 10M

WEIGHT

41kg

INTERPRETED BY

Nele Eley (Ondreka),
DVM Dr. med. vet.,
DipECVDI

**IMAGING
PERFORMED BY**

Mobile Pet Imaging

HOSPITAL NAME

Mobile Pet Imaging

REFERRING VET

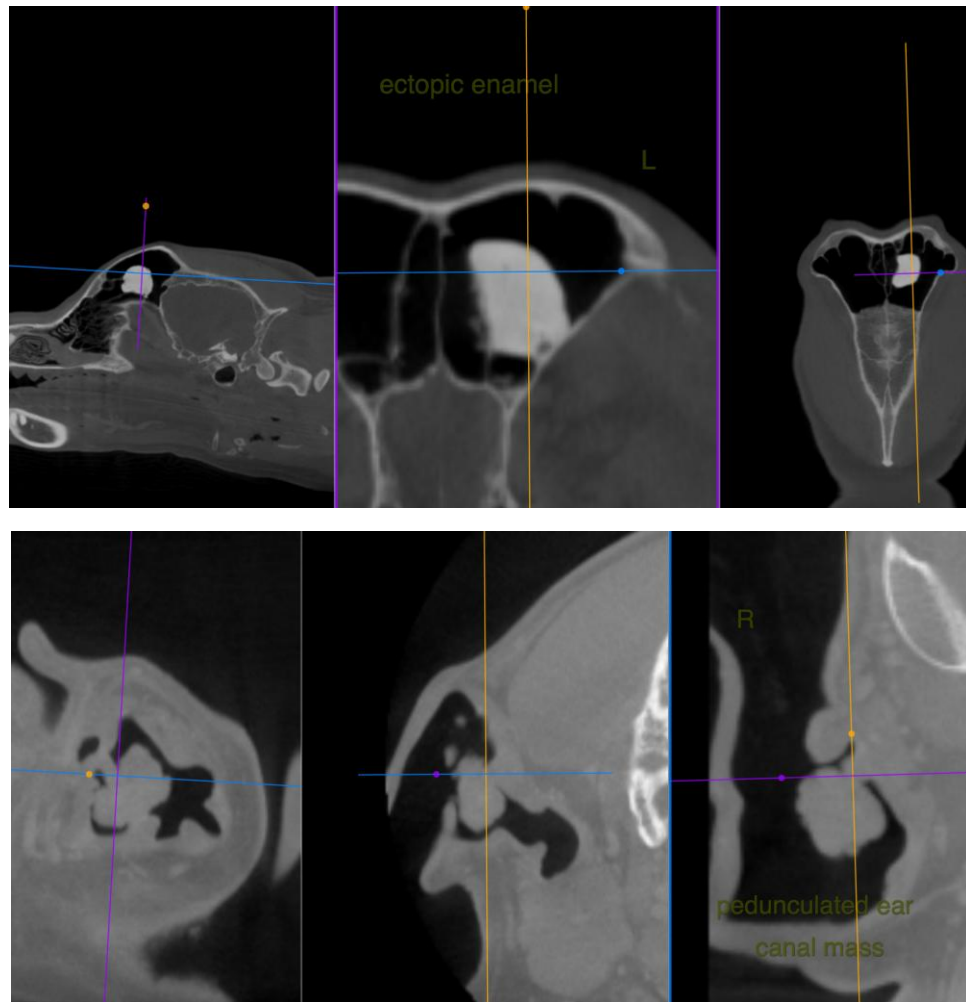
Armstrong

INVOICE

72799

DATE

12-1-25



The information and recommendations provided are based on the images presented by the referring veterinarian. No evaluation can be communicated regarding pathology that was not visible in the image/video clips provided.

Thank you for this referral. If the clinical or image interpretation does not parallel your findings or if I can be of any further assistance please contact me.

Nele Eley (Ondreka), DVM, Dr. med. vet., DipECVDI
European Specialist in Veterinary Diagnostic Imaging, Cert. Radiology,
Senior lecturer University of Giessen/Germany, Veterinary Faculty, Department of Radiology.
info@sonopath.com