



**PATIENT**

T.J. Hunziker

**PRESENTING CLINICAL SIGNS**

Presented last week for vomiting and inappetence. Blood panel showed azotemia (BUN 139, creat 5.0), calcium 14.2, phos > 15, moderately elevated liver enzymes (chronic), cPLi abnormal. P was hospitalized for symptomatic treatment and symptoms resolved. Re-presented today for decreased appetite and mild lethargy. No known dietary indiscretion.

**SPECIES**

Canine

Abnormal PE/Chem/CBC/UA Results: Grade 2-3/6 systolic heart murmur. Pink, tacky mm. Comfortable abdomen. Blood panel today: neutrophils 13.39 H, BUN 136, creat 6.0, phos > 15, calcium 12.0 (normal), stable liver enzyme elevations. Leptospirosis test pending.

**RADIOGRAPHIC STUDY OF THE ABDOMEN**

**BREED**

Pomeranian Mix

Lateral and ventrodorsal views of the thorax and abdomen totaling 4 images available for review.

Abdominal read requested.

**SEX**

MN

**RADIOGRAPHIC FINDINGS**

Mineral opacities superimpose onto the soft tissues ventral of the caudal abdominal wall.

Size, shape, and opacity of the liver and spleen are considered within normal limits.

**AGE**

12 Years

The radiographic presentation of the kidneys and urinary bladder are considered within normal limits as well.

**INTERPRETED BY**

Nele Eley, DVM  
Dr. med. Vet. DipECVDI

A geometrically shaped mineral opaque structure with sharp margins is seen within the gastric fundus. This structure measures approximately 12mm in length and 10mm in width. The remainder of the stomach appears to be empty.

Turgid appearance of the nondilated small intestinal loops is seen.

The colon is filled with a small amount of fecal material only.

**HOSPITAL NAME**

Paws and Claws  
Urgent Care

Both coxofemoral joints present moderate osteoarthritic changes.

**RADIOGRAPHIC DIAGNOSIS**

- Gastric foreign material.
- Small intestinal maldigestion pattern.
- Mineral opacities ventral of the caudal abdominal wall.

**REFERRING VET**

Alexis Rambaud

**INTERPRETATION OF THE FINDINGS & FURTHER RECOMMENDATIONS**

**INVOICE**

48694

The radiographic study reveals presence of gastric foreign material with relatively sharp margins. Based on the opacity, the material may represent plastic and less likely glass or osseous structures. Endoscopic removal of the foreign material could be considered barring the presumably sharp margins in mind. The structure appears to be too large to pass the natural way. Consider potential for concurrent enteropathy.

**DATE**

12-1-21

The mineral opacities in the soft tissues caudal of the ventral abdominal wall most likely represent foci of dystrophic mineralization versus metaplasia of the abdominal wall musculature.



**PATIENT**

T.J. Hunziker

**SPECIES**

Canine

**BREED**

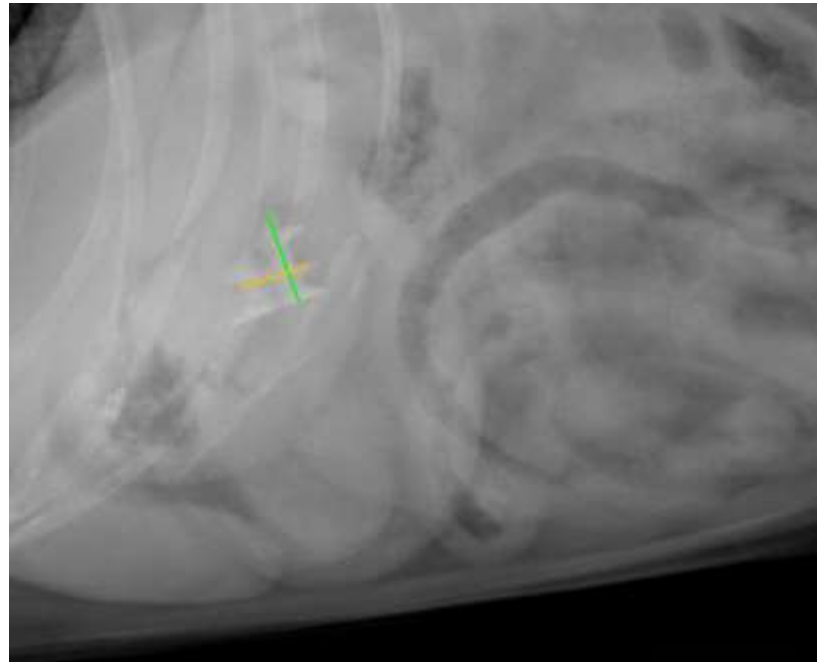
Pomeranian Mix

**SEX**

MN

**AGE**

12 Years



**INTERPRETED BY**

Nele Eley, DVM  
Dr. med. Vet. DipECVDI

**HOSPITAL NAME**

Paws and Claws  
Urgent Care

**REFERRING VET**

Alexis Rambaud

**INVOICE**

48694

**DATE**

12-1-21

The information and recommendations provided are based on the images presented by the referring veterinarian. No evaluation can be communicated regarding pathology that was not visible in the image/video clips provided.

Thank you for this referral. If the clinical or image interpretation does not parallel your findings or if I can be of any further assistance please contact me.

**Nele Eley**, DVM, Dr. med. vet., DipECVDI  
European Specialist in Veterinary Diagnostic Imaging, Cert. Radiology,  
Senior lecturer University of Giessen, Germany, Veterinary Faculty, Department of Radiology  
Nele.Eley@sonopath.com