

**PATIENT**

PASHA ERDOGAN

PRESENTING CLINICAL SIGNS

Reason for Visit: Annual History: P presents for annual exam and bw. O states P is also due for zycortal inj. O mentioned P has been trying to bite when she lifts his tail to clean him. Groomer also noted P have a similar reaction.

SPECIES

Canine

Abnormal PE/Chem/CBC/UA Results: CV/Respiratory: Normal heart rate and rhythm, no murmur, pulses strong and synchronous, normal bronchovesicular sounds. EENT: Clear OU and AU. No nasal discharge. No cough on tracheal palpation. Oral cavity: Moderate dental tartar, underbite, halitosis Musculoskeletal: BCS = 5/9. Ambulatory x 4. Uro/Perineum: No significant lesions Abd/GI: Soft, non-painful. No masses or fluid wave palpated Lymph Nodes: No peripheral lymphadenopathy Neurological: Alert and appropriate. No significant abnormalities Skin: Soft tissue swelling at tail base, painful when move tail up (flexion) and to the R side. Good hair coat. No ectoparasites seen Mentation: BAR Hydration: N

BREED

Havanese Mix

RADIOGRAPHIC STUDY OF THE TAIL**SEX**

Lateral and ventrodorsal views totaling 2 images available for review.

NM**RADIOGRAPHIC FINDINGS****AGE**

9 Years, 8 Months

Moderate swelling dorsal of the 5th coccygeal vertebra is seen which tapers down caudally up to the level of the 9th coccygeal vertebra. There is no evidence of associated osseous changes. No traumatic osseous injury is seen and no osteolytic or osteoproliferative lesions are noted.

RADIOGRAPHIC DIAGNOSIS

- Unspecific regional soft tissue swelling at the tail base without associated osseous changes.

INTERPRETED BY

Nele Eley, DVM
Dr. med. Vet. DipECVDI

INTERPRETATION OF THE FINDINGS & FURTHER RECOMMENDATIONS**HOSPITAL NAME**

DPC Veterinary
Hospital

Differential diagnosis includes early neoplasia as well as traumatic injury and inflammation / infection. Further definition by means of fine needle aspiration is recommended if not performed already.

REFERRING VET

Dr. Rivera

INVOICE

48695

DATE

12-1-21



PATIENT

PASHA ERDOGAN

SPECIES

Canine

BREED

Havanese Mix

SEX

NM

AGE

9 Years, 8 Months

INTERPRETED BY

Nele Eley, DVM
Dr. med. Vet. DipECVDI

HOSPITAL NAME

DPC Veterinary
Hospital

REFERRING VET

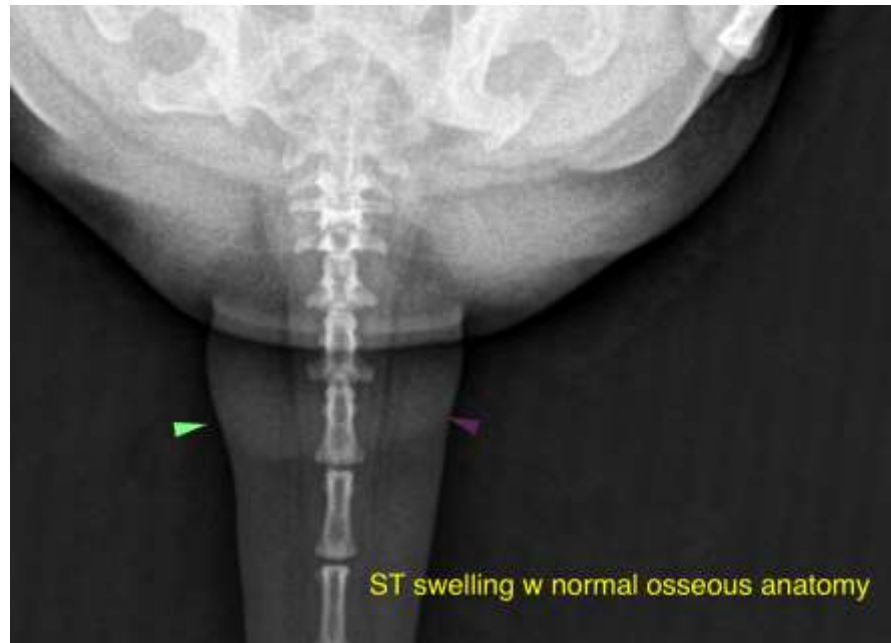
Dr. Rivera

INVOICE

48695

DATE

12-1-21



The information and recommendations provided are based on the images presented by the referring veterinarian. No evaluation can be communicated regarding pathology that was not visible in the image/video clips provided.

Thank you for this referral. If the clinical or image interpretation does not parallel your findings or if I can be of any further assistance please contact me.

Nele Eley, DVM, Dr. med. vet., DipECVDI
European Specialist in Veterinary Diagnostic Imaging, Cert. Radiology,
Senior lecturer University of Giessen, Germany, Veterinary Faculty, Department of Radiology
Nele.Eley@sonopath.com