



## PATIENT PRESENTING CLINICAL SIGNS

**PATIENT** Butters Holm  
**SPECIES** P presented for coughing, hyporexia, lethargy and open mouth breathing that progressed over the last week. Indoor only with no other animals in house, or exposure to other pets. Dental with extractions-no teeth left-about 2 months ago. BW at that time was normal per o. Today, very aggressive, Increased effort but no panting. Harsh, dry cough noted. Unable to hear lungs due to vocalization. Administer torb and albuterol prior to rads.

Feline

Abnormal PE/Chem/CBC/UA Results: CBC: WNL Chem: Crea 2.8, BUN 38, Na 167, Triple Snap: Neg USG: 1.025

## BREED

DSH

## RADIOGRAPHIC STUDY OF THE THORAX

Right/left lateral and ventrodorsal views of the thorax are available for review.

## SEX

MN

## RADIOGRAPHIC FINDINGS

Mild age-related cranial rotation of the cardiac silhouette is noted. The overall size and shape of the cardiac silhouette are within normal limits. The vertebral heart score is 7.2, which is within the reference range. No evidence of congestive changes or chamber enlargement is seen.

## AGE

11yr

A moderate generalized bronchial pattern with increased bronchial wall markings is seen throughout the right and left lung field. Mild pulmonary overinflation is noted. Peribronchial cuffing and mild interstitial changes are present. There are no discrete alveolar infiltrates, consolidations, or mass lesions.

## INTERPRETED BY

Nele Eley (Ondreka),  
DVM Dr. med. vet.,  
DipECVDI

The trachea is normal in diameter and course.

The mediastinum is normal in width and position.

The stomach and intestines appear mildly distended with gas.

## HOSPITAL NAME

Mountain West  
Veterinary Specialists

Mild generalized osteopenia is noted.

## RADIOGRAPHIC DIAGNOSIS

- Moderate generalized bronchial lung pattern
- Deep pulmonary inflation
- Gastrointestinal aerophagia.
- Normal radiographic presentation of the cardiac silhouette.

## REFERRING VET

Reagan Vadell

## INVOICE

22918

## INTERPRETATION OF FINDINGS & FURTHER RECOMMENDATIONS

The radiographic study reveals no evidence of cardiovascular disease. The findings are consistent with chronic lower airway disease, most likely allergic/ feline asthma with mild air trapping. There is no radiographic evidence of pneumonia, mass lesions, or severe pulmonary compromise. Infectious bronchitis is a possible, yet by far less likely, differential diagnosis.

## DATE

11/09/2025

The mild gastrointestinal distension is likely secondary to a mild gastrointestinal aerophagia. Clinical



**PATIENT** correlation is recommended.

**Butters Holm** Consider medical management with bronchodilators and /or corticosteroids or other asthma therapy as indicated. Monitor gastrointestinal distension. Avoid exposure to respiratory irritants such as smoke, perfumes, chemicals, and other. Airway sampling could be considered for further definition to rule out ongoing bronchitis in case of lacking response to treatment.

**SPECIES**

Feline

**BREED**

DSH

**SEX**

MN

**AGE**

11yr

**INTERPRETED BY**

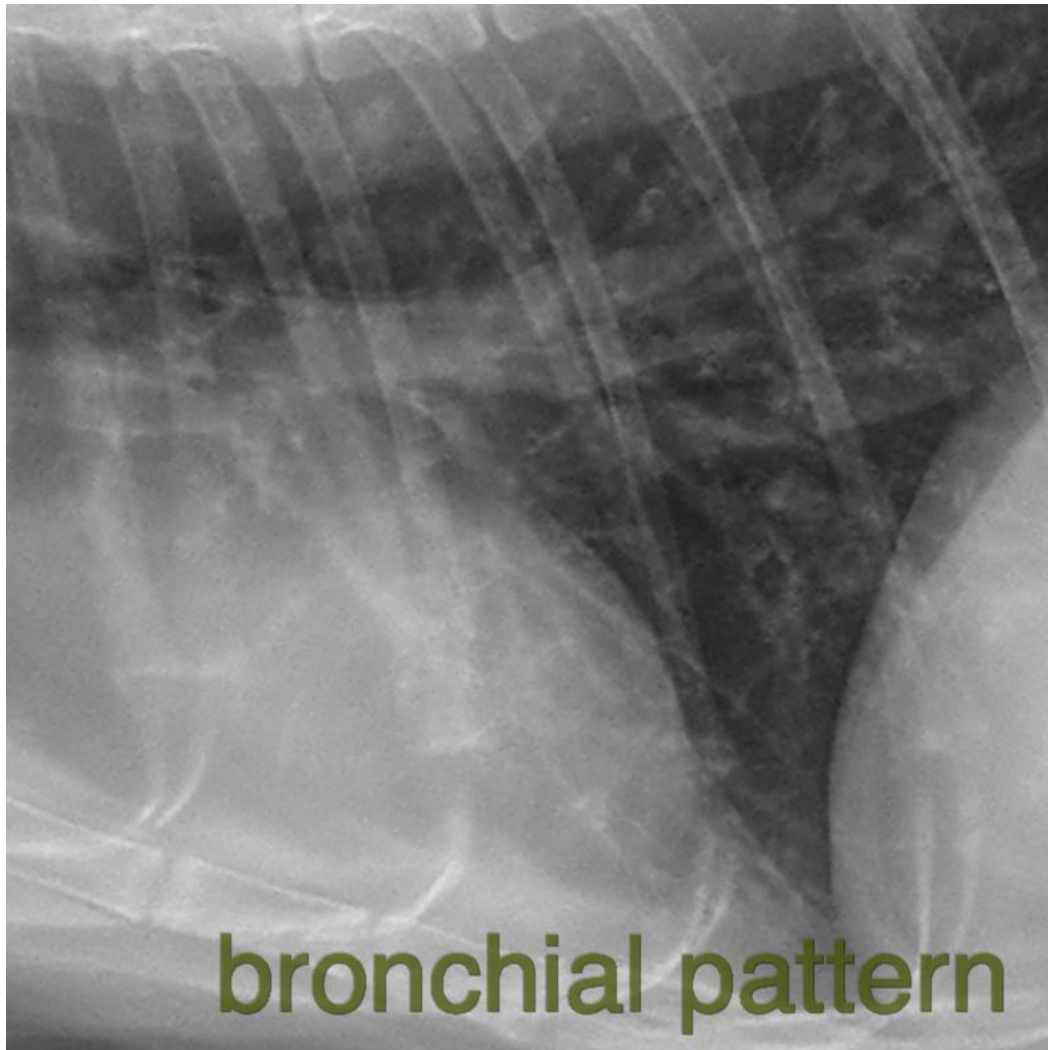
Nele Eley (Ondreka),  
DVM Dr. med. vet.,  
DipECVDI

**HOSPITAL NAME**

Mountain West  
Veterinary Specialists

**REFERRING VET**

Reagan Vadell



**INVOICE**

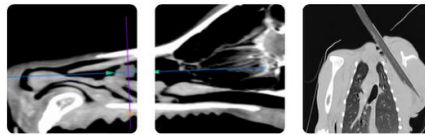
22918

**DATE**

11/09/2025

The information and recommendations provided are based on the images presented by the referring veterinarian. No evaluation can be communicated regarding pathology that was not visible in the image/video clips provided.

Thank you for this referral. If the clinical or image interpretation does not parallel your findings or if I can be of any further assistance please contact me.



## PATIENT

Butters Holm  
Nele Eley (Ondreka), DVM, Dr. med. vet., DipECVDI  
European Specialist in Veterinary Diagnostic Imaging, Cert. Radiology,  
Senior lecturer University of Giessen/Germany, Veterinary Faculty, Department of Radiology.  
[info@sonopath.com](mailto:info@sonopath.com)

## SPECIES

Feline

## BREED

DSH

## SEX

MN

## AGE

11yr

## INTERPRETED BY

Nele Eley (Ondreka),  
DVM Dr. med. vet.,  
DipECVDI

## HOSPITAL NAME

Mountain West  
Veterinary Specialists

## REFERRING VET

Reagan Vadell

## INVOICE

22918

## DATE

11/09/2025