

**PATIENT**

Zina Desth

PRESENTING CLINICAL SIGNS

left front limb lameness rule out orthopedic versus neurologic

SPECIES

Canine

COMPUTED TOMOGRAPHIC STUDY OF THE CERVICAL SPINE

Myelogram with cervical puncture available for review.

BREED

Lab Mix

COMPUTED TOMOGRAPHIC FINDINGS

Three sites of intervertebral disc protrusion are seen throughout the cervical spine including C2/3, C5/6, and C6/7. The protrusions between C5/6 and C6/7 are more pronounced on the right side of the ventral epidural space. The protrusion C6/7 is moderate in degree. The protrusion at C5/6 is considered mild. Moderate protrusion is noted at C2/3 with left sided accentuation.

SEX

FS

Chondroid disc degeneration of the T1/2 intervertebral disc is seen.

A mild canalogram is noted.

AGE

8 Years

COMPUTED TOMOGRAPHIC DIAGNOSIS

- Moderate chronic left sided intervertebral disc protrusion C2/3.
- Mild chronic right sided intervertebral disc protrusion C5/6.
- Moderate chronic right sided intervertebral disc protrusion C6/7.
- Chondroid disc degeneration T1/2.

INTERPRETED BYNele Eley, DVM
Dr. med. Vet. DipECVDI**INTERPRETATION OF THE FINDINGS & FURTHER RECOMMENDATIONS**

The CT study reveals multiple mild to moderate intervertebral disc protrusions with chronic appearance in the cervical spine. The one that carries potential to correlate with the clinical signs is the protrusion at C2/3 since it is accentuating the left side. The protrusions within the deep cervical spine at C5/6 and C6/7 may well be of clinical significance based on their volume however both present right sided accentuation.

HOSPITAL NAMEAnimal Surgical
Center**REFERRING VET**Good Ground Animal
Hospital**INVOICE**

55102

DATE

11-9-22



PATIENT

Zina Desth

SPECIES

Canine

BREED

Lab Mix

SEX

FS

AGE

8 Years

INTERPRETED BY

Nele Eley, DVM
Dr. med. Vet. DipECVDI

HOSPITAL NAME

Animal Surgical
Center

REFERRING VET

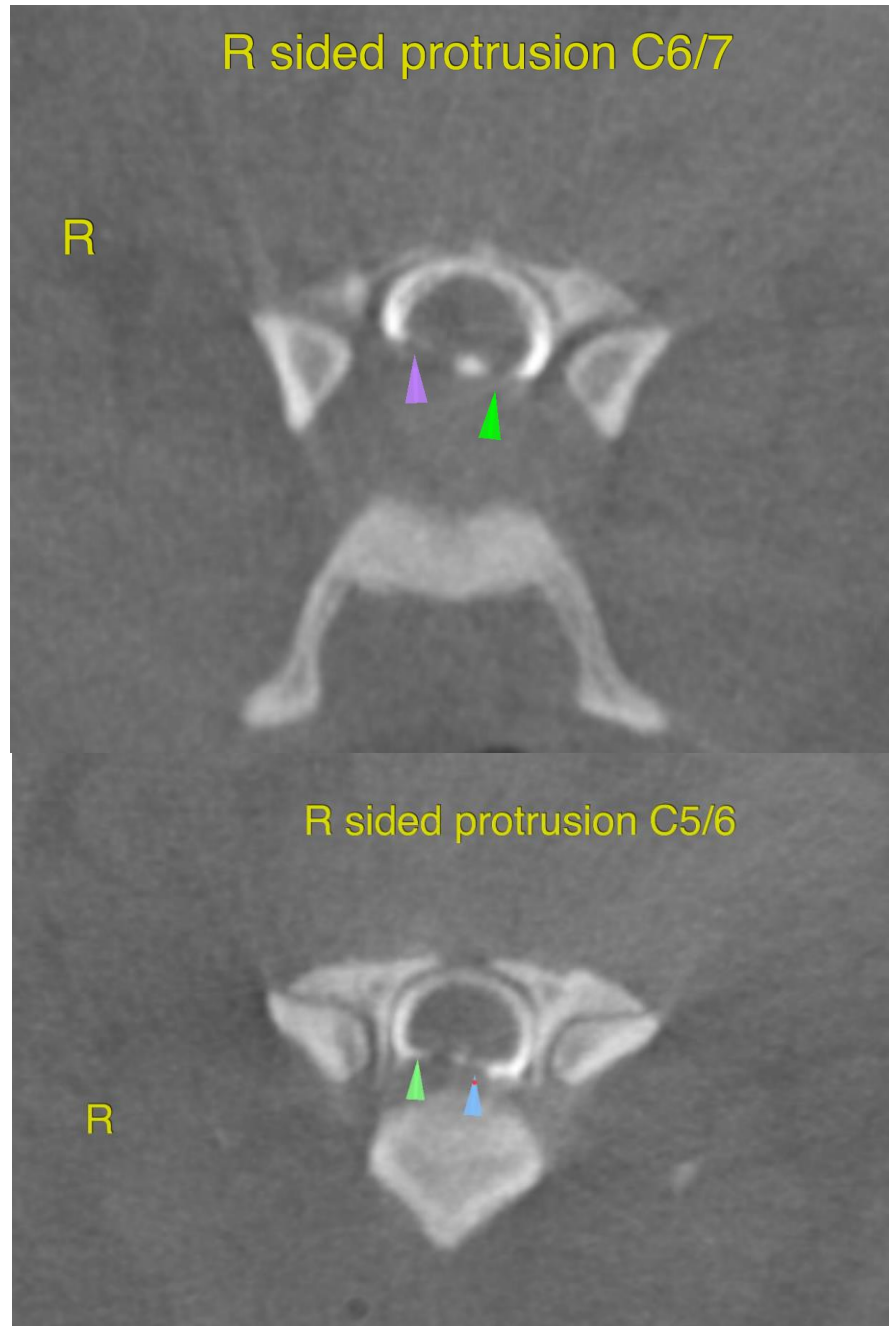
Good Ground Animal
Hospital

INVOICE

55102

DATE

11-9-22





PATIENT

Zina Desth

SPECIES

Canine

BREED

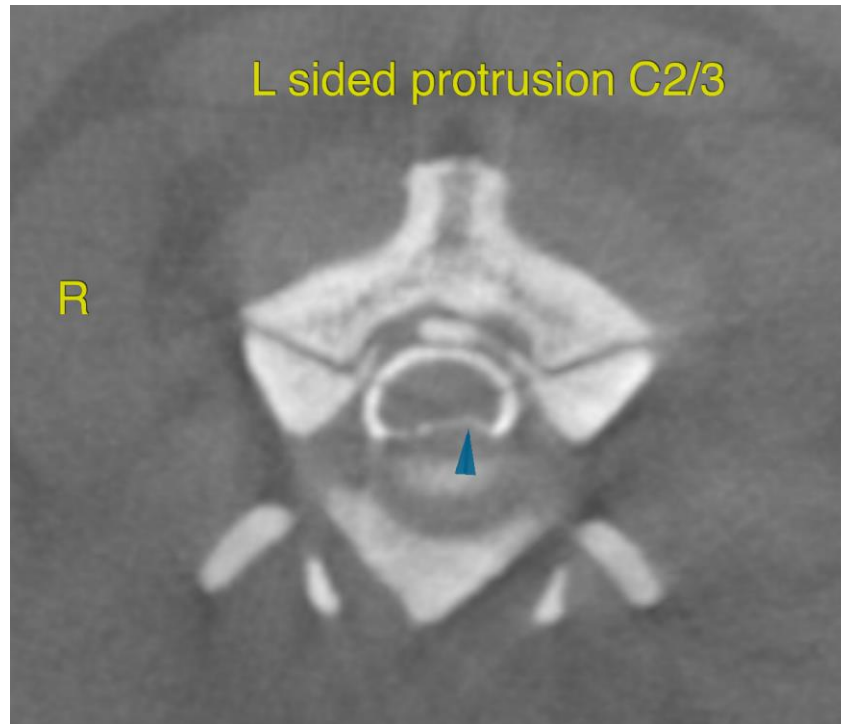
Lab Mix

SEX

FS

AGE

8 Years



INTERPRETED BY

Nele Eley, DVM
Dr. med. Vet. DipECVDI

The information and recommendations provided are based on the images presented by the referring veterinarian/sonographer. No evaluation can be communicated regarding pathology that was not visible in the image/video clips provided.

HOSPITAL NAME

Animal Surgical
Center

Thank you for this referral. If the clinical or image interpretation does not parallel your findings or if I can be of any further assistance please contact me.

REFERRING VET

Good Ground Animal
Hospital

Nele Eley, DVM, Dr. med. vet., DipECVDI
European Specialist in Veterinary Diagnostic Imaging, Cert. Radiology,
Senior lecturer University of Giessen, Germany, Veterinary Faculty, Department of Radiology
Nele.Eley@sonopath.com

INVOICE

55102

DATE

11-9-22