



PATIENT

Oscar Lim Huey Yiing

SPECIES

Canine

BREED

Siberian Husky

SEX

Male

AGE

10 Years, 11 Months

INTERPRETED BY

Nele Eley, DVM
Dr. med. Vet. DipECVDI

HOSPITAL NAME

Animal Medical
Centre Sdn Bhd

REFERRING VET

Dr. Sivan

INVOICE

55080

DATE

11-9-22

PRESENTING CLINICAL SIGNS

September 2022 removed growth from oral cavity, biopsy result revealed SCC. Now tumor growing again. To assess the extent of the growth at right gingiva. CT thorax done and no lungs metastasis seen.

COMPUTED TOMOGRAPHIC STUDY OF THE HEAD

Plain and post contrast studies available for review.

COMPUTED TOMOGRAPHIC FINDINGS

Patient has a history of regrowing squamous cell carcinoma of the right gingiva margin.

A 3.5 x 2.5 x 2.5 cm sized soft tissue mass is seen in the right maxillary gingival margin with buccal, oral, and nasal extension. The mass centers the triadans 107 and 108 which present multiple lytic changes of their enamel and cementum with dental loosening and widening of their dental alveolus. The intranasal soft tissue component of the mass occupies the lateral and ventral aspect of the mid third of the right nasal cavity. Regional turbinate destruction is noted. No significant aggressive osteolytic changes are seen distal to the triadan 108 within the right maxillary arcade.

Multifocal moderate periodontal space widening is noted accentuating the triadans 105, 206, and 209.

The regional retropharyngeal and submandibular lymph nodes present within normal limits.

COMPUTED TOMOGRAPHIC DIAGNOSIS

- Soft tissue mass with aggressive biological behavior and secondary bone lysis in the right gingival alveolar margin with oral and intranasal extension.

INTERPRETATION OF THE FINDINGS & FURTHER RECOMMENDATIONS

The CT findings are compatible with a malignant soft tissue neoplasia of the right alveolar gingival margin which presents oral and intranasal extension as well as secondary aggressive osteolysis. The findings are compatible with the history of regrowing squamous cell carcinoma.

No evidence of regional lymphadenomegaly was noted.



PATIENT

Oscar Lim Huey Yiing

SPECIES

Canine

BREED

Siberian Husky

SEX

Male

AGE

10 Years, 11 Months

INTERPRETED BY

Nele Eley, DVM
Dr. med. Vet. DipECVDI

HOSPITAL NAME

Animal Medical
Centre Sdn Bhd

REFERRING VET

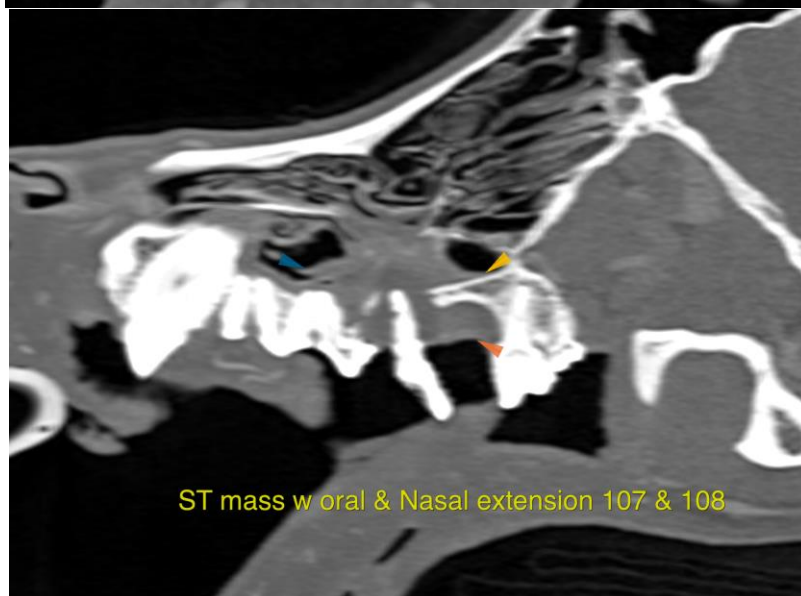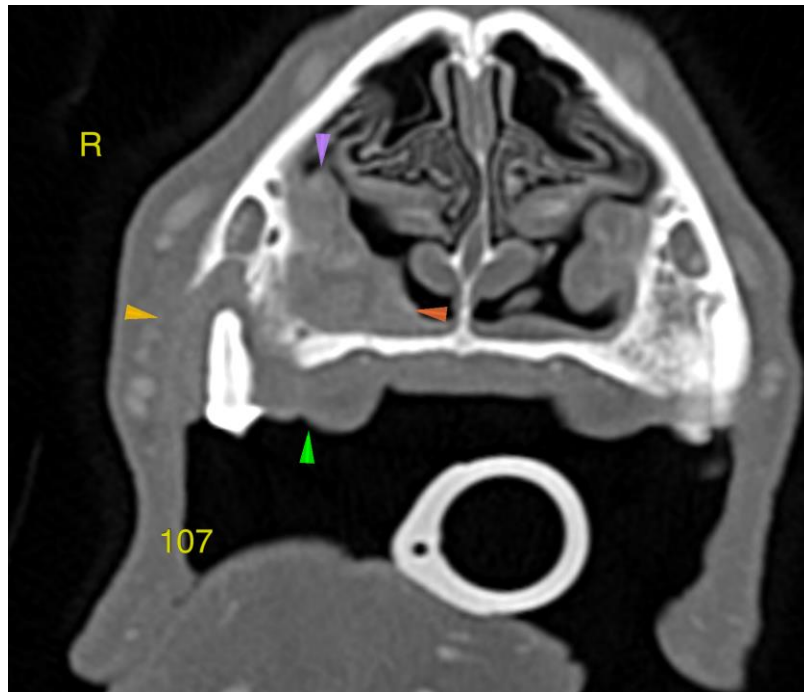
Dr. Sivan

INVOICE

55080

DATE

11-9-22





PATIENT

Oscar Lim Huey Yiing

The information and recommendations provided are based on the images presented by the referring veterinarian/sonographer. No evaluation can be communicated regarding pathology that was not visible in the image/video clips provided.

SPECIES

Canine

Thank you for this referral. If the clinical or image interpretation does not parallel your findings or if I can be of any further assistance please contact me.

BREED

Siberian Husky

Nele Eley, DVM, Dr. med. vet., DipECVDI
European Specialist in Veterinary Diagnostic Imaging, Cert. Radiology,
Senior lecturer University of Giessen, Germany, Veterinary Faculty, Department of Radiology
Nele.Eley@sonopath.com

SEX

Male

AGE

10 Years, 11 Months

INTERPRETED BY

Nele Eley, DVM
Dr. med. Vet. DipECVDI

HOSPITAL NAME

Animal Medical
Centre Sdn Bhd

REFERRING VET

Dr. Sivan

INVOICE

55080

DATE

11-9-22