



PATIENT

Brew Lacey

PRESENTING CLINICAL SIGNS

Limping on the right rear stifle for greater than a month
 Abnormal PE/Chem/CBC/UA Results: Medial buttress, Cranial drawer and CTT Blood work WNL X-rays 1. Moderate right stifle effusion and arthritis compatible with an intra-articular injury such as a cranial cruciate ligament rupture. 2. Subtle left stifle arthritis. 3. Possible osteochondrosis dissecans of the articular surface of the medial malleolus of the right leg. This is of unknown clinical significance at this time given the lack of effusion and arthritis. 4. Unremarkable pelvis. 5. Unremarkable thorax. 6. Unremarkable abdomen.

SPECIES

Canine

BREED

Retriever Mix

ULTRASONOGRAPHIC FINDINGS

Right Stifle

A mild to moderate amount of anechoic effusion is seen within the supra- and infra-patellar recesses of the right stifle joint. Moderate swelling of the synovium and a moderate amount of periarticular osteophytes are noted. There is mild heterogeneity of the infrapatellar fat pad.

SEX

MN

The cranial cruciate ligament is remarkably ill-defined and surrounded by a hypoechoic halo. Generalized thickening, echogenic foci, and stripes are noted within the ligament.

AGE

7 Years

The lateral and medial menisci are in situ with well delineated margins and uniform internal architecture.

ULTRASONOGRAPHIC DIAGNOSIS

- Mild to moderate right stifle osteoarthritis with cranial cruciate ligament pathology.

INTERPRETED BY

Nele Eley, DVM
 Dr. med. Vet. DipECVDI

INTERPRETATION OF THE FINDINGS & FURTHER RECOMMENDATIONS

The ultrasonographic findings strongly support presence of cruciate ligament pathology. Partial rupture is considered likely based on the ultrasonographic findings. The echogenic foci and stripes are likely to represent disrupted cruciate ligament fibers. Mild to moderate concurrent osteoarthritic changes are seen and there is no structural evidence of meniscopathy at this point.

HOSPITAL NAME

Westview Veterinary
 Hospital

REFERRING VET

Dr. Brian Barnes

INVOICE

55081

DATE

11-9-22



PATIENT

Brew Lacey

SPECIES

Canine

BREED

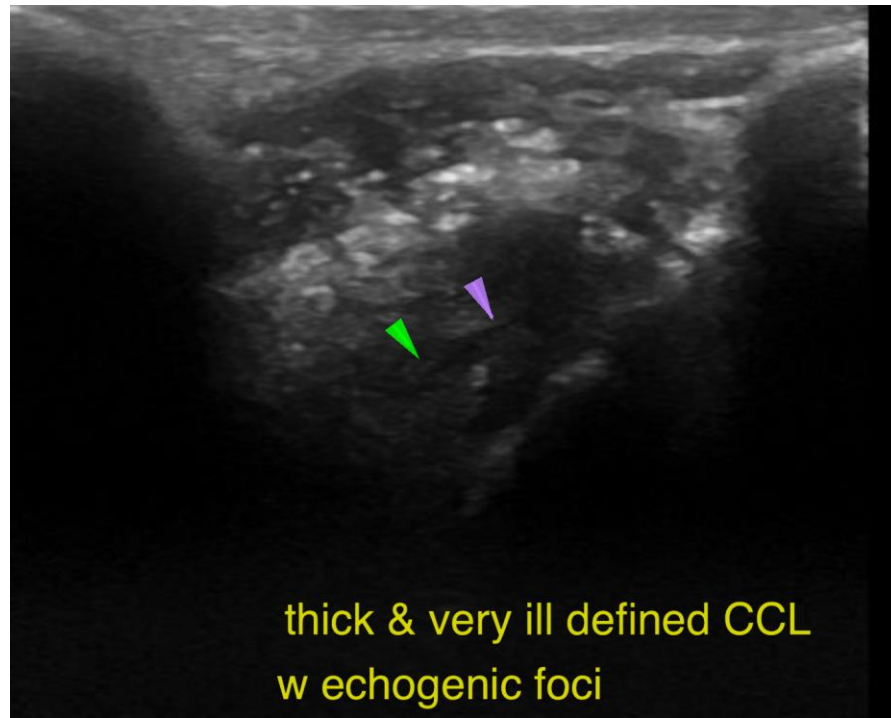
Retriever Mix

SEX

MN

AGE

7 Years



INTERPRETED BY

Nele Eley, DVM
Dr. med. Vet. DipECVDI

The information and recommendations provided are based on the images presented by the referring veterinarian/sonographer. No evaluation can be communicated regarding pathology that was not visible in the image/video clips provided.

Thank you for this referral. If the clinical or image interpretation does not parallel your findings or if I can be of any further assistance please contact me.

HOSPITAL NAME

Westview Veterinary
Hospital

Nele Eley, DVM, Dr. med. vet., DipECVDI
European Specialist in Veterinary Diagnostic Imaging, Cert. Radiology,
Senior lecturer University of Giessen, Germany, Veterinary Faculty, Department of Radiology
Nele.Eley@sonopath.com

REFERRING VET

Dr. Brian Barnes

INVOICE

55081

DATE

11-9-22