



**PATIENT PRESENTING CLINICAL SIGNS**

Logan Martinez Firm and enlarged left kidney.

**COMPUTED TOMOGRAPHIC STUDY OF THE ABDOMEN**

**SPECIES** Plain and post contrast studies available for review.

Rabbit

**COMPUTED TOMOGRAPHIC FINDINGS**

**BREED** The serosal fat presents normal attenuation behavior. There is no evidence of peritoneal effusion or peritonitis.

Lionhead

**SEX**

Female

The left kidney is enlarged and presents severe dilation of its renal pelvis. The cortex and medulla cannot be differentiated and are deviated and compressed towards the periphery. The left kidney measures 3.3 cm in length compared with 2.4 cm of the right kidney. The left ureter is moderately dilated with a diameter of 5mm. The dilation can be traced from the renal pelvis to the caudal abdomen where a cluster of mineral attenuating foci is seen within the ureter and the dilation of the ureter ends. The right kidney and right ureter present within normal limits.

**AGE**

3

The adrenal glands are within normal limits for size, shape and organ architecture. Both liver and spleen present with normal shape, even surface, uniformly attenuating parenchyma and homogeneous contrast enhancement, unremarkable.

**INTERPRETED BY**

Nele Eley (Ondreka),  
DVM Dr. med. vet.,  
DipECVDI

The pancreas is evenly contoured, the pancreatic parenchyma is homogeneous and presents uniform contrast enhancement.

The position, delineation, wall and content of the gastrointestinal tract are considered within normal limits throughout.

The bony and surrounding soft tissue structures reveal no abnormalities.

**HOSPITAL NAME**

Mobile Pet Imaging  
CFL

**COMPUTED TOMOGRAPHIC DIAGNOSIS**

- Left sided hydroureter and hydronephrosis due to ureteral obstruction with presumed urinary calculi. Differential diagnosis: granuloma or neoplasia.

**REFERRING VET**

Xavier Meaux

**INTERPRETATION OF FINDINGS & FURTHER RECOMMENDATIONS**

The CT findings are compatible with left ureteral obstruction. The obstruction contains several mineral attenuating foci which may represent urinary bladder calculi. Granuloma or neoplasia are potential but less likely differential diagnoses. Nephrectomy and ureterectomy with consecutive histopathological examination of the obstruction site could be considered.

**INVOICE**

55017

**DATE**

11-8-22



**PATIENT**

Logan Martinez

**SPECIES**

Rabbit

**BREED**

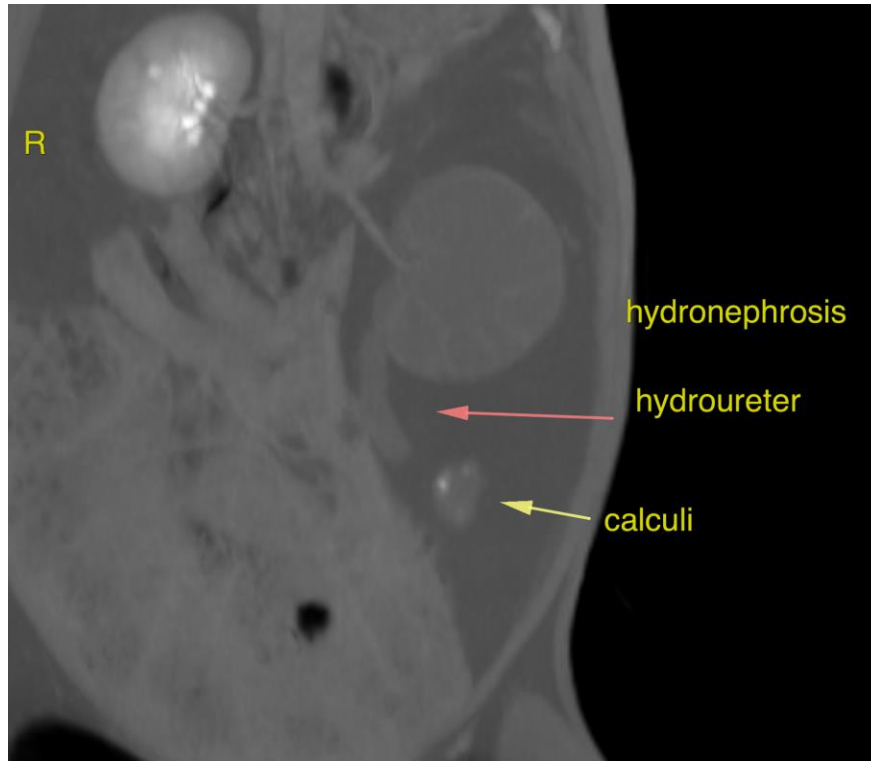
Lionhead

**SEX**

Female

**AGE**

3



**INTERPRETED BY**

Nele Eley (Ondreka),  
DVM Dr. med. vet.,  
DipECVDI

The information and recommendations provided are based on the images presented by the referring veterinarian. No evaluation can be communicated regarding pathology that was not visible in the image/video clips provided.

Thank you for this referral. If the clinical or image interpretation does not parallel your findings or if I can be of any further assistance please contact me.

**HOSPITAL NAME**

Mobile Pet Imaging  
CFL

**Nele Eley (Ondreka)**, DVM, Dr. med. vet., DipECVDI  
European Specialist in Veterinary Diagnostic Imaging, Cert. Radiology,  
Senior lecturer University of Giessen/Germany, Veterinary Faculty, Department of Radiology.  
Nele.Eley@sonopath.com

**REFERRING VET**

Xavier Meaux

**INVOICE**

55017

**DATE**

11-8-22