



**PATIENT**

Leroy Brovege

**PRESENTING CLINICAL SIGNS**

Leroy has been limping on his front left leg and they have tried to give him bed rest but they have 2 other days and Leroy likes to play rough. He will play in the morning and after a nap will be sore. He doesn't lick his limb and it isn't swollen.

**SPECIES**

Canine

Abnormal PE/Chem/CBC/UA Results: MUSCLE ATROPHY LEFT FRONT, GRADE I TO II LAME LEFT FRONT. NO PAIN ISOLATED, GOOD RANGE OF MOTION. Some pain with extension of elbows.

**BREED**

Labrador Retriever

**RADIOGRAPHIC STUDY OF THE PELVIS, SHOULDERS, & ELBOWS**

Ventrodorsal and lateral views of the pelvis, mediolateral and craniocaudal views of the shoulders, and mediolateral neutral and flexed and craniocaudal views of the elbows totaling 12 images available for review.

**SEX**

Male

**RADIOGRAPHIC FINDINGS**

**Pelvis**

The coxofemoral joints present within normal limits. The femoral heads are well developed and deeply situated within the acetabular grooves. The joint spaces are even and narrow with no evidence of joint space divergence or subluxation. Femoral head coverage is adequate.

**AGE**

6 Months, 2 Weeks

No evidence of osteoarthritic changes is seen.

**INTERPRETED BY**

Nele Eley, DVM  
Dr. med. Vet. DipECVDI

The sacrum and lumbosacral junction present within normal limits.

**Shoulders**

Both shoulders present within normal limits. There is no evidence of osteochondritis or other articular injury.

**HOSPITAL NAME**

Elizabeth Animal  
Hospital

**Elbows**

Blurring and decreased opacity as well as deformity of the medial coronoid process are noted in the left elbow. There is a deep subchondral bone defect within the medial humeral condyle surrounded by peripheral sclerosis. A mild amount of periarticular osteophytes and subtrochlear notch sclerosis of the ulna are seen.

**REFERRING VET**

Kim Allyn, DVM

Subtrochlear notch sclerosis of the ulna is seen in the right elbow as well. There is however no evidence of subchondral bone defects, and the medial coronoid process appears to be well delineated and well mineralized.

**INVOICE**

55063

**RADIOGRAPHIC DIAGNOSIS**

- Medial coronoid pathology and subchondral bone defect within the medial humeral condyle in the left elbow with mild secondary osteoarthritic changes.
- Mild sclerosis of the subtrochlear notch of the ulna in the right elbow.
- Radiographically normal shoulder and coxofemoral joints.

**DATE**

11-8-22



**PATIENT**

Leroy Brovege

**SPECIES**

Canine

**BREED**

Labrador Retriever

**SEX**

Male

**AGE**

6 Months, 2 Weeks

**INTERPRETED BY**

Nele Eley, DVM  
Dr. med. Vet. DipECVDI

**HOSPITAL NAME**

Elizabeth Animal  
Hospital

**REFERRING VET**

Kim Allyn, DVM

**INVOICE**

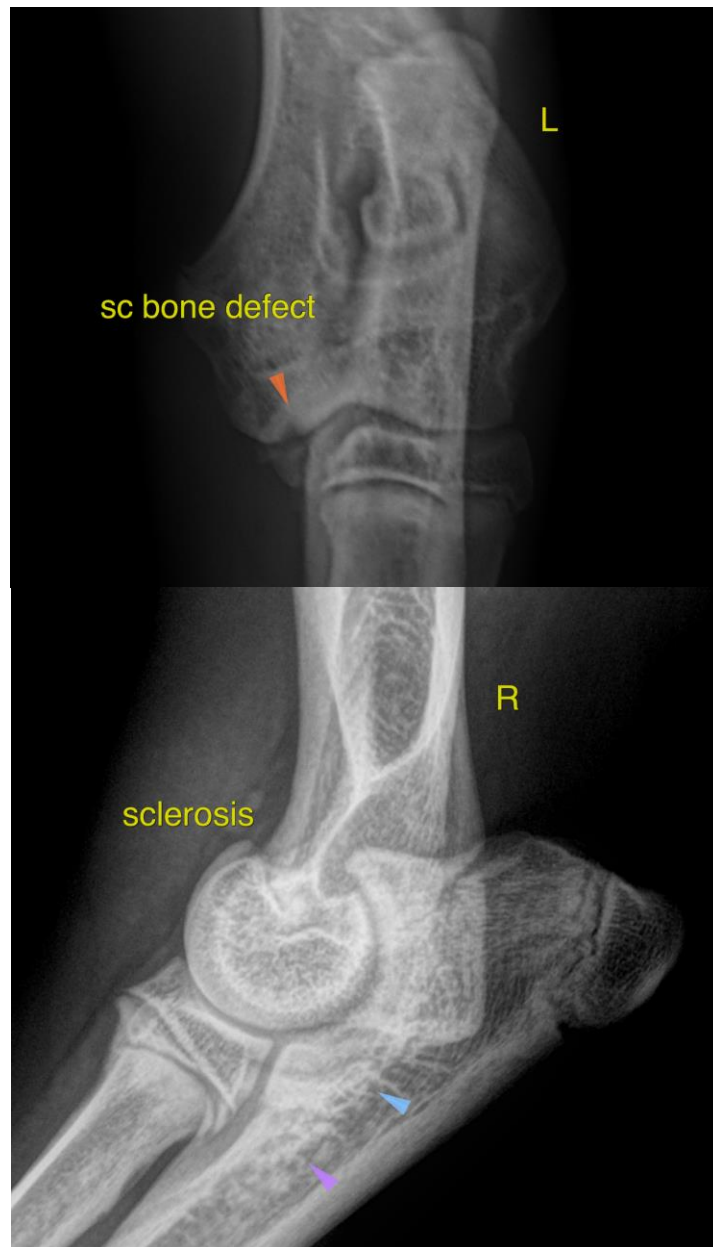
55063

**DATE**

11-8-22

**INTERPRETATION OF THE FINDINGS & FURTHER RECOMMENDATIONS**

The radiographic study reveals mild left elbow osteoarthritis which is remarkable for a skeletally immature patient. The osteoarthritis is secondary to medial coronoid pathology and osteochondritis of the medial humeral condyle. A kissing lesion would be a potential differential diagnosis for the subchondral bone defect in the medial humeral condyle however osteochondritis is considered more likely based on the patient age and position of the defect. Further workup by means of CT and arthroscopic revision of the left elbow should be considered.





**PATIENT**

Leroy Brovege

**SPECIES**

Canine

**BREED**

Labrador Retriever

**SEX**

Male

**AGE**

6 Months, 2 Weeks

**INTERPRETED BY**

Nele Eley, DVM  
Dr. med. Vet. DipECVDI

**HOSPITAL NAME**

Elizabeth Animal  
Hospital

**REFERRING VET**

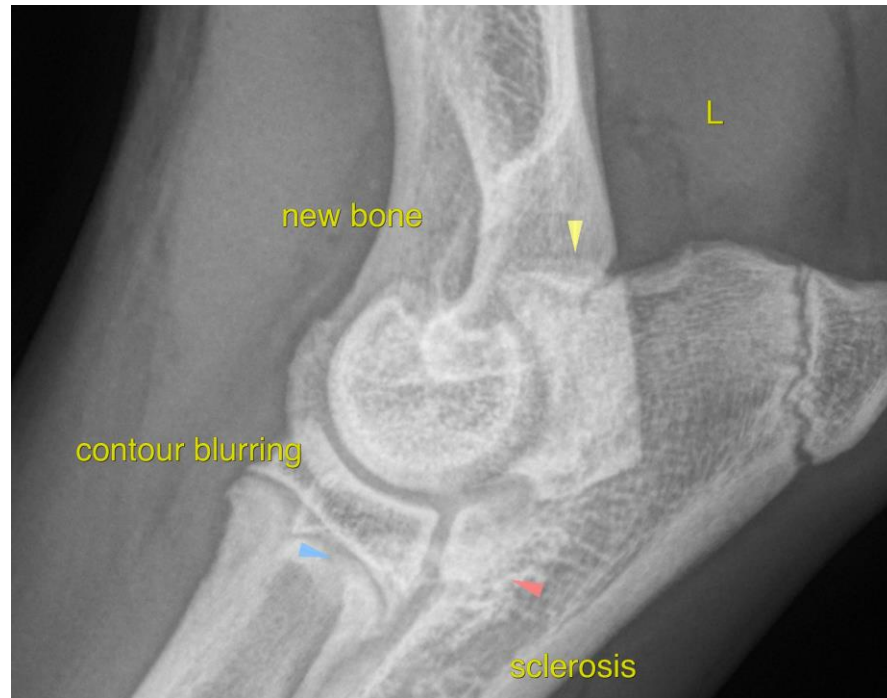Kim Allyn, DVM

**INVOICE**

55063

**DATE**

11-8-22



The information and recommendations provided are based on the images presented by the referring veterinarian/sonographer. No evaluation can be communicated regarding pathology that was not visible in the image/video clips provided.

Thank you for this referral. If the clinical or image interpretation does not parallel your findings or if I can be of any further assistance please contact me.

**Nele Eley**, DVM, Dr. med. vet., DipECVDI  
European Specialist in Veterinary Diagnostic Imaging, Cert. Radiology,  
Senior lecturer University of Giessen, Germany, Veterinary Faculty, Department of Radiology  
Nele.Eley@sonopath.com