

**PATIENT**

Maximus Thomas

**PRESENTING CLINICAL SIGNS**

Stable patient with long chronic history of back pain  
Abnormal PE/Chem/CBC/UA Results: Eyes: bright and clear Ears: clean with no inflammation  
Nose and throat: no abnormality Heart: No noted arrhythmia or pulse deficits, normal subjective  
peripheral circulation Lungs: normal respiratory sounds, rate and effort Abdomen: soft and non-  
painful with no noted abnormalities Musculoskeletal: No significant musculoskeletal  
abnormalities or lameness Integument: Clean and smooth hair coat Lymph Nodes: Normal size  
and firmness Neurological: Abnormal: cranial nerves and metation are normal. The fore limbs are  
normal. There is mild to moderate discomfort on back palpation. hind legs show delayed CP and  
normal reflexes. The hind limbs shake substantially. T3-L3 Myelopathy

**SPECIES**

Canine

**BREED**

Schnauzer

**MAGNETIC RESONANCE IMAGING STUDY OF THE THORACOLUMBAR JUNCTION**

T1-plain and post contrast and T2-weighted images available for review.

**SEX**

MN

**MAGNETIC RESONANCE IMAGING FINDINGS**

Multiple intervertebral discs show mild to moderate reduction of their T2 hyperintense nucleus  
pulposus signal. The majority of the disc are in situ.

**AGE**

11 Years

Mild mid-sagittal intervertebral disc protrusion into the ventral epidural space of the vertebral  
canal is seen at T12/13.

Mild to moderate protrusions are present at T13/L1 and L1/2. However, there is no associated  
spinal cord swelling and the dorsal csf and fat compartments are maintained.

**INTERPRETED BY**

Nele Eley, DVM  
Dr. med. Vet. DipECVDI

Minimal protrusion is seen at T10/11.

**MAGNETIC RESONANCE IMAGING DIAGNOSIS**

- Mild to moderate chronic intervertebral disc protrusions T13/L1 and L1/2.
- Mild chronic intervertebral disc protrusion T12/13.

**HOSPITAL NAME**

Mountain West  
Veterinary Hospital

**INTERPRETATION OF THE FINDINGS & FURTHER RECOMMENDATIONS**

The MRI findings appear to parallel the history of chronic back pain. Mild to moderate  
protrusions are seen in the thoracolumbar junction area between T13/L1, L1/2, and T12/13. At  
this point, no spinal cord compression is seen and there is no evidence of spinal cord gliosis or  
malacia.

**REFERRING VET**

Burton

**INVOICE**

48293

**DATE**

11-8-21



**PATIENT**

Maximus Thomas

**SPECIES**

Canine

**BREED**

Schnauzer

**SEX**

MN

**AGE**

11 Years

**INTERPRETED BY**

Nele Eley, DVM  
Dr. med. Vet. DipECVDI

**HOSPITAL NAME**

Mountain West  
Veterinary Hospital

**REFERRING VET**

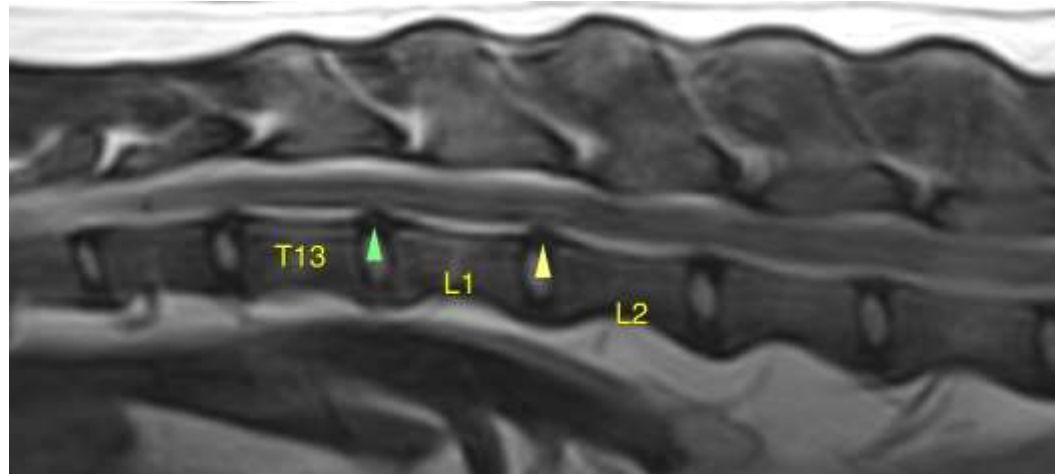
Burton

**INVOICE**

48293

**DATE**

11-8-21



The information and recommendations provided are based on the images presented by the referring veterinarian. No evaluation can be communicated regarding pathology that was not visible in the image/video clips provided.

Thank you for this referral. If the clinical or image interpretation does not parallel your findings or if I can be of any further assistance please contact me.

**Nele Eley, DVM, Dr. med. vet., DipECVDI**  
European Specialist in Veterinary Diagnostic Imaging, Cert. Radiology,  
Senior lecturer University of Giessen, Germany, Veterinary Faculty, Department of Radiology  
Nele.Eley@sonopath.com