



PATIENT

Max Frank

PRESENTING CLINICAL SIGNS

Severe Bilateral Stifle OA with thrust RH and suspected CCL pathology

SPECIES

Canine

ULTRASONOGRAPHIC FINDINGS

Right Stifle

Moderate to severe osteoarthritic changes with moderate effusion within the supra- and infra-patellar recesses, osteophytosis, and synovial proliferations are noted.

BREED

Lab X

The cranial cruciate ligament is discontinuous and presents as an echogenic stump at the intercondylar eminence of the tibia surrounded by a hypoechoic halo.

ULTRASONOGRAPHIC DIAGNOSIS

SEX

MN

- Moderate to severe right stifle osteoarthritis.
- Complete rupture in the cranial cruciate ligament.

INTERPRETATION OF THE FINDINGS & FURTHER RECOMMENDATIONS

AGE

5 Years

The ultrasonographic study reveals complete rupture of the cranial cruciate ligament in the right stifle. The osteoarthritic changes are moderate to severe.

INTERPRETED BY

Nele Eley, DVM
Dr. med. Vet. DipECVDI

HOSPITAL NAME

Foxfield Veterinary
Services

REFERRING VET

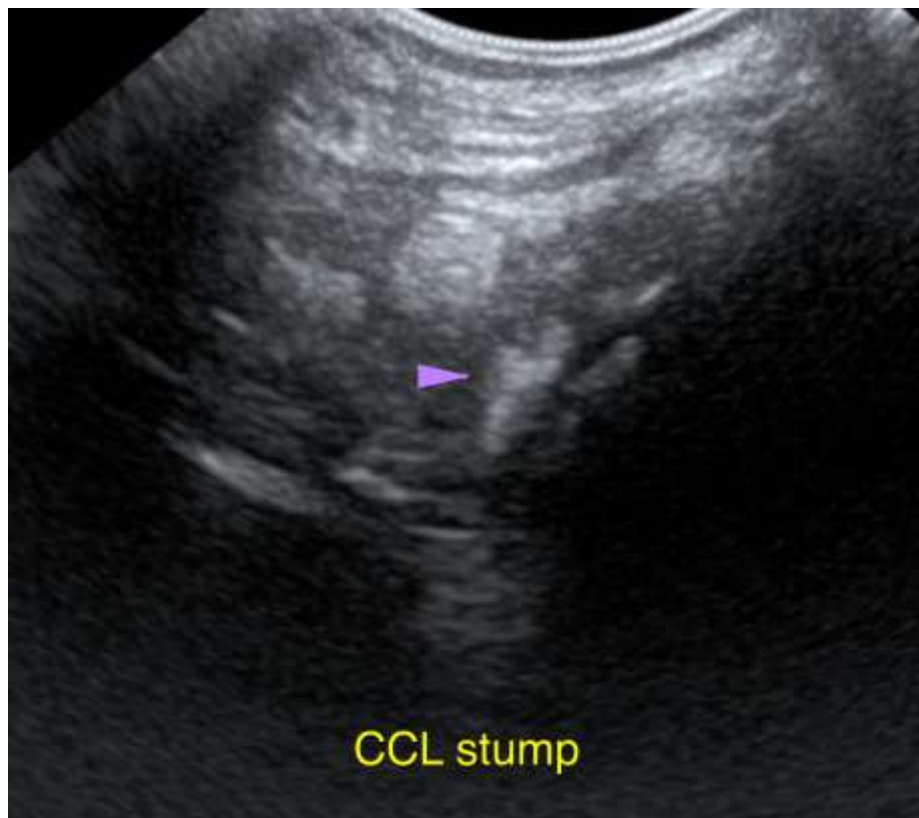
Rodriguez

INVOICE

48294

DATE

11-8-21





PATIENT

Max Frank

The information and recommendations provided are based on the images presented by the referring veterinarian. No evaluation can be communicated regarding pathology that was not visible in the image/video clips provided.

SPECIES

Canine

Thank you for this referral. If the clinical or image interpretation does not parallel your findings or if I can be of any further assistance please contact me.

BREED

Lab X

Nele Eley, DVM, Dr. med. vet., DipECVDI
European Specialist in Veterinary Diagnostic Imaging, Cert. Radiology,
Senior lecturer University of Giessen, Germany, Veterinary Faculty, Department of Radiology
Nele.Eley@sonopath.com

SEX

MN

AGE

5 Years

INTERPRETED BY

Nele Eley, DVM
Dr. med. Vet. DipECVDI

HOSPITAL NAME

Foxfield Veterinary
Services

REFERRING VET

Rodriguez

INVOICE

48294

DATE

11-8-21