



PATIENT

Missy Gillem

PRESENTING CLINICAL SIGNS

Patient presented for acute facial swelling. She got into the trash a few days prior to presentation and subsequently stopped eating. Was noted to have right facial swelling this morning. On presentation, there is bilateral buphthalmos, worse on the right, with decreased retropulsion of OD. Right side of muzzle progressively swelling. On oral exam, there is a necrotic, infected line of tissue on the right hard palate with severe surrounding gingivitis. No foreign bodies noted in oral cavity. Patient is also having blood-tinged nasal discharge. Submandibular lymphadenopathy appreciated on exam.

SPECIES

Canine

BREED

German Shepherd

COMPUTED TOMOGRAPHIC STUDY OF THE HEAD

Plain and post contrast studies available for review.

COMPUTED TOMOGRAPHIC FINDINGS

SEX

FI

Diffuse soft tissue swelling is seen in the right and left side of the face accentuating the right side. There is increased heterogeneous contrast enhancement in the area of the subcutaneous and interfascial soft tissue swelling with subcutaneous fluid accumulation along the right masseter muscle. Multiple lingual and facial veins present extensive thrombosis in the right side of the face which can be traced caudally to feed into the right jugular vein which appears to be completely obliterated by a thrombus as well. The thrombus crosses the midline via the transverse basilingual vein and feeds into the left lingual vein as well with a smaller tail of the thrombus. No foreign material can be identified.

AGE

5 Years

INTERPRETED BY

Nele Eley, DVM
Dr. med. Vet. DipECVDI

Both the left and right medial retropharyngeal and submandibular lymph nodes present moderate symmetric enlargement.

No structural abnormality of the retrobulbar soft tissues is seen on either side.

HOSPITAL NAME

Animal Emergency
Hospital Deland

There is a moderate amount of fluid attenuating material present within the rostral third of the right nasal cavity. The left nasal cavity presents within normal limits.

COMPUTED TOMOGRAPHIC DIAGNOSIS

- Extensive thrombosis of the right facial, lingual, and jugular veins with severe peripheral cellulitis and regional lymphadenitis.

REFERRING VET

Dr. Schwanebeck

INTERPRETATION OF THE FINDINGS & FURTHER RECOMMENDATIONS

Diffuse cellulitis in the right and to a lesser degree in the left side of the face is seen as well as multiple venous thrombi within the right lingual, facial, and jugular veins. Cellulitis and thrombophlebitis are considered likely. A direct structural cause cannot be identified however septic thrombosis and a hypercoagulable state appear to be the primary differential diagnoses. Further internal medicine workup could be considered as well as sampling the subcutaneous fluid from the right side of the face.

INVOICE

55045

DATE

11-7-22

The lymph node changes are compatible with reactive lymphadenitis. Fine needle aspiration of the lymph nodes could be considered for further definition in order to rule out differential diagnoses such as round cell neoplasia.



PATIENT

Missy Gillem

SPECIES

Canine

BREED

German Shepherd

SEX

FI

AGE

5 Years

INTERPRETED BY

Nele Eley, DVM
Dr. med. Vet. DipECVDI

HOSPITAL NAME

Animal Emergency
Hospital Deland

REFERRING VET

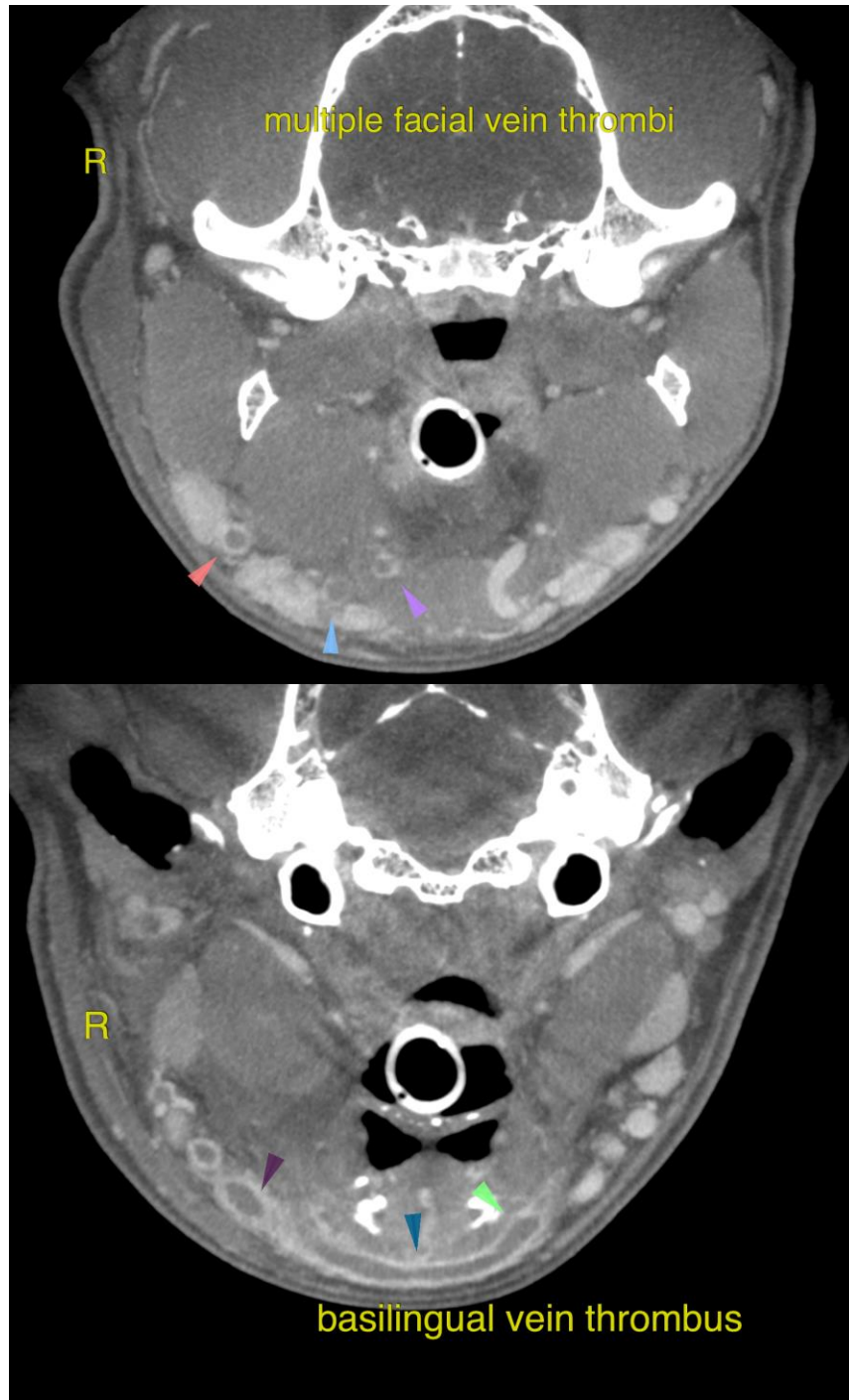
Dr. Schwanebeck

INVOICE

55045

DATE

11-7-22





PATIENT

Missy Gillem

The information and recommendations provided are based on the images presented by the referring veterinarian/sonographer. No evaluation can be communicated regarding pathology that was not visible in the image/video clips provided.

Thank you for this referral. If the clinical or image interpretation does not parallel your findings or if I can be of any further assistance please contact me.

SPECIES

Canine

Nele Eley, DVM, Dr. med. vet., DipECVDI
European Specialist in Veterinary Diagnostic Imaging, Cert. Radiology,
Senior lecturer University of Giessen, Germany, Veterinary Faculty, Department of Radiology
Nele.Eley@sonopath.com

BREED

German Shepherd

SEX

FI

AGE

5 Years

INTERPRETED BY

Nele Eley, DVM
Dr. med. Vet. DipECVDI

HOSPITAL NAME

Animal Emergency
Hospital Deland

REFERRING VET

Dr. Schwanebeck

INVOICE

55045

DATE

11-7-22