



**PATIENT**

Egypt Caviness

**PRESENTING CLINICAL SIGNS**

Vomiting & diarrhea for 3 days weight loss  
Abnormal PE/Chem/CBC/UA Results: pending

**SPECIES**

Canine

**RADIOGRAPHIC STUDY OF THE ABDOMEN**

Right lateral and ventrodorsal views of the abdomen totaling 2 images available for review.

**BREED**

Mini Schnauzer Mix

**RADIOGRAPHIC FINDINGS**

Mild generalized osteopenia is noted and considered within age related normal limits.

There is mild generalized enlargement of the liver with slightly rounded lobar margins.

**SEX**

Female/sp

The stomach presents moderate aerophagia.

The small intestinal loops appear to be evenly distributed throughout the mid abdomen. Small intestinal crowding is noted. No significant dilation of the small intestine can be identified.

**AGE**

15 Years

The colon contains a mild amount of fecal matter only.

**RADIOGRAPHIC DIAGNOSIS**

- Mild generalized hepatomegaly
- Gastric aerophagia
- Small intestinal crowding.

**INTERPRETED BY**

Nele Eley, DVM  
Dr. med. Vet. DipECVDI

**INTERPRETATION OF THE FINDINGS & FURTHER RECOMMENDATIONS**

The radiographic findings are unspecific. Gastroenteropathy is a potential however definitive and significant structural changes cannot be identified. Further definition by means of abdominal ultrasound is strongly recommended with the pertinent clinical signs and patient demographics if not performed already.

**HOSPITAL NAME**

New Bridge  
Veterinary Practice

Differential diagnosis for the hepatomegaly includes vacuolar degeneration, metabolic/endocrine hepatopathy, and diffuse inflammation/infection, or infiltrative disease. The changes appear to be rather mild. Correlation with the laboratory values and eventually with the ultrasonographic findings is recommended.

**REFERRING VET**

Dr. Abina Glennon

**INVOICE**

55039

**DATE**

11-7-22



**PATIENT**

Egypt Caviness

**SPECIES**

Canine

**BREED**

Mini Schnauzer Mix

**SEX**

Female/sp

**AGE**

15 Years

**INTERPRETED BY**

Nele Eley, DVM  
Dr. med. Vet. DipECVDI

**HOSPITAL NAME**

New Bridge  
Veterinary Practice

**REFERRING VET**

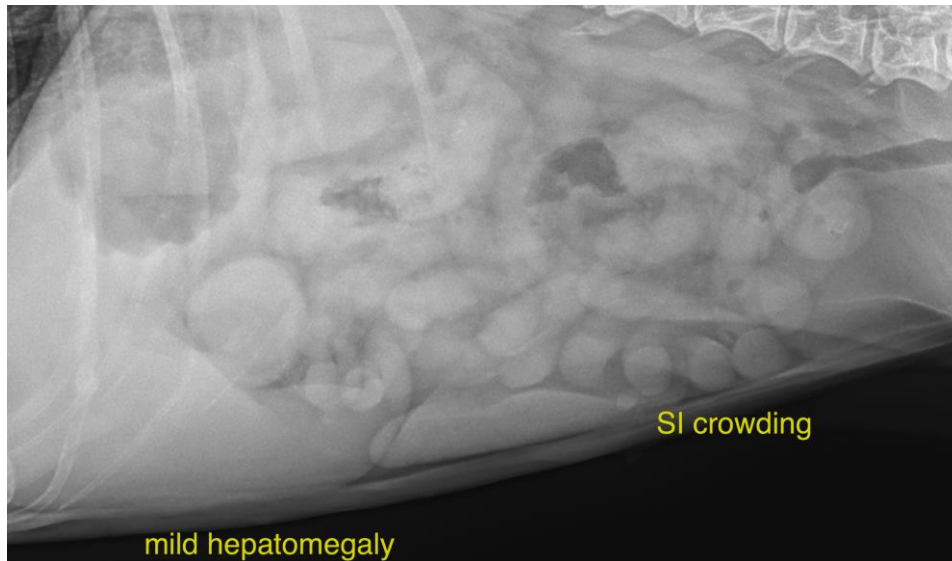
Dr. Abina Glennon

**INVOICE**

55039

**DATE**

11-7-22



The information and recommendations provided are based on the images presented by the referring veterinarian/sonographer. No evaluation can be communicated regarding pathology that was not visible in the image/video clips provided.

Thank you for this referral. If the clinical or image interpretation does not parallel your findings or if I can be of any further assistance please contact me.

**Nele Eley**, DVM, Dr. med. vet., DipECVDI  
European Specialist in Veterinary Diagnostic Imaging, Cert. Radiology,  
Senior lecturer University of Giessen, Germany, Veterinary Faculty, Department of Radiology  
Nele.Eley@sonopath.com