



PATIENT

Toby Vocaturo

PRESENTING CLINICAL SIGNS

coughing for 3 weeks sounds like choking
Abnormal PE/Chem/CBC/UA Results: cbc,chem/fecal : pending

SPECIES

Canine

RADIOGRAPHIC STUDY OF THE THORAX

6 images available for review with right/left lateral and ventrodorsal projections included.

BREED

Lab

RADIOGRAPHIC FINDINGS

The degree of pulmonary inflation is moderate. A moderate cranioventral alveolar lung pattern with patchy distribution is noted and accentuates the left lung. The remainder of the lung presents a moderate generalized interstitial infiltrate with peribronchial accentuation.

SEX

MN

Mild esophageal aerophagia is noted.

AGE

7 Years

Course and width of the trachea are considered within normal limits.

The cardiac silhouette presents within normal limits. There is no evidence of specific chamber enlargement. The pulmonary vasculature is thin. No mediastinal mass effect is seen.

The thoracic boundaries present within normal limits.

INTERPRETED BY

Nele Eley, DVM
Dr. med. Vet. DipECVDI

RADIOGRAPHIC DIAGNOSIS

- Cranioventral alveolar lung pattern with left sided accentuation and concurrent interstitial increase in opacity.

INTERPRETATION OF THE FINDINGS & FURTHER RECOMMENDATIONS

HOSPITAL NAME

CJAH

The radiographic findings are compatible with bronchopneumonia. Infectious bronchopneumonia is considered likely in this patient. Lobar neoplasia and pulmonary hemorrhage are theoretical but by far less likely differential diagnoses. Further definition by means of airway endoscopy with airway sampling could be considered and weighed against a clinical trial of antimicrobial treatment with clinical and radiographic recheck.

REFERRING VET

Gabriel

INVOICE

55012

DATE

11-5-22



PATIENT

Toby Vocaturo

SPECIES

Canine

BREED

Lab

SEX

MN

AGE

7 Years

INTERPRETED BY

Nele Eley, DVM
Dr. med. Vet. DipECVDI

HOSPITAL NAME

CJAH

REFERRING VET

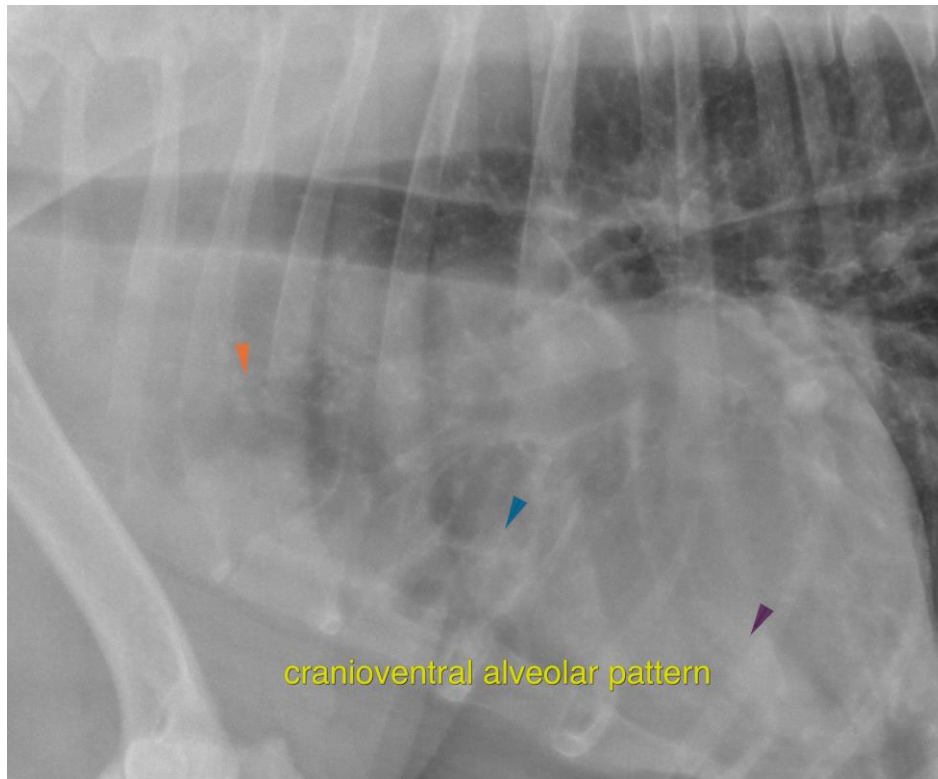
Gabriel

INVOICE

55012

DATE

11-5-22



The information and recommendations provided are based on the images presented by the referring veterinarian/sonographer. No evaluation can be communicated regarding pathology that was not visible in the image/video clips provided.

Thank you for this referral. If the clinical or image interpretation does not parallel your findings or if I can be of any further assistance please contact me.

Nele Eley, DVM, Dr. med. vet., DipECVDI
European Specialist in Veterinary Diagnostic Imaging, Cert. Radiology,
Senior lecturer University of Giessen, Germany, Veterinary Faculty, Department of Radiology
Nele.Eley@sonopath.com